

The periodontal examination and consultation

The diagnostic components

Murray L. Arlin, D.D.S., F.R.C.D.(C)

An essential component of every dental examination should include a careful periodontal screening. In those cases where significant disease is present, a complete periodontal examination, diagnosis and treatment plan is indicated. In such cases, the periodontal documentation that is required cannot be written down in detail on most standard dental forms. For this reason it is extremely important to have a separate form specifically to be used for your "periodontal patients". Interested readers are referred to an article in *Oral Health*, (October issue 1985, page 17) by this author titled "Periodontal Assessment Forms".

The present article integrates closely with the previous one on "Periodontal Assessment Forms" in that the reader should be aware of all the diagnostic components included in a periodontal examination and on an assessment form.

The present article, however will discuss in some detail only, four diagnostic parameters, namely 1) periodontal probing 2) tooth mobility – malocclusion 3) furcation involvement, and 4) gingival recession – mucogingival defects. These four parameters comprise the data that can be most conveniently recorded on your assessment form by carrying out four separate examination "circuits" around the mouth. Other important diagnostic procedures for eg. radiographic analysis

Dr. Arlin has a private periodontics practice in Toronto.

We are pleased to present the first publication of this article, written especially for *Oral Health*.

will not be addressed in this article. The next step that follows the information gathering phase is formulating your "Diagnosis, Prognosis and Treatment Plan", however these will be the subject of a future publication. At this stage one would be ready for the "Patient Consultation" and the latter part of this article will discuss this very important step. Although many aspects of consultation are common to all types of dental treatment, this article will highlight some important components that are especially relevant to the "periodontal consultation".

1.) Periodontal probing

Your periodontal assessment form preferably should be able to accommodate at least two series of measurements to coincide with the initial examination, and the re-evaluation (which should be done two-three months following completion of initial therapy). The periodontal probe is perhaps the single most useful diagnostic tool for assessing the severity of periodontal attachment loss. It is important also to be aware of the proper



Fig. 1. "Walk" the probe in the sulcus to map out the topography of the attachment level.

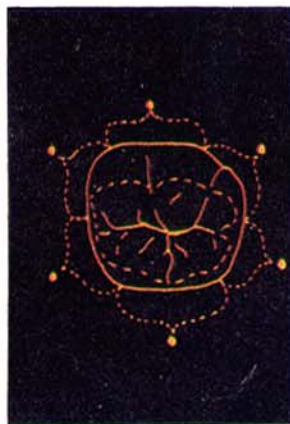


Fig. 2. Each of the six point measurements should represent the point of deepest penetration representing $\frac{1}{6}$ of the circumference.

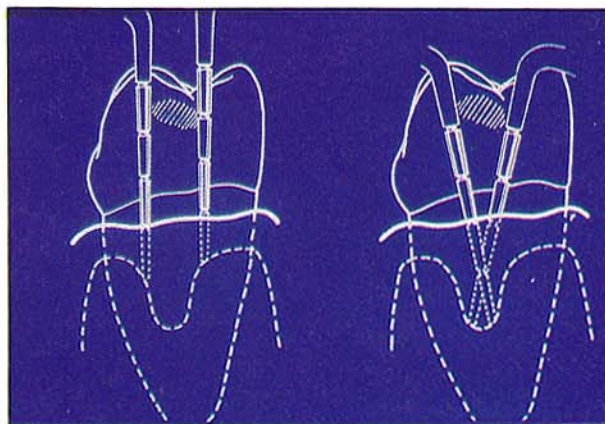


Fig. 3. It is important to angle the probe in order not to miss areas of attachment loss that are commonly located apical to the interproximal contact.

technique and proper interpretation of the measurements. The periodontal probe should be placed along the long axis of the tooth. "Walk" the probe (Fig. 1) along the tooth using "light" pressure and record six measurements per tooth. Each measurement should represent the point of deepest penetration around $\frac{1}{6}$ area of the circumference (Fig. 2) ie. 1) mid-buccal 2) mesio-buccal 3) disto-buccal 4) mid-lingual 5) mesio-lingual and 6) disto-lingual. Areas that freely bleed on probing can be highlighted with a dot over the pocket measurement (while a small "e" can denote exudate). When measuring the interproximal area it is important to slightly angle the probe below the contact area in order to diagnose any existing areas of attachment loss (Fig. 3). As well, to be consistent one should "round up" any fractional measurements to the next highest millimeter. Although probing can be an accurate diagnostic test¹, the interpretation of the probing measurements has recently received increasing attention amongst investigators (references 10, 14, 15, 17, 18, 20). The recorded pocket depth and histological position of the probe tip can be a function of many factors such as a) probing force applied b) angle of insertion of the probe c) exact location point of measurement d) probe diameter e) tissue tone (ie inflammation?) f) examiner error and g) probe manufacturer's inaccuracies.

A simplistic summary of our present understanding based on the research findings is as follows: 1) Bleeding on probing (B.O.P.) reflects histological, clinical and bacteriological alterations associated with periodontal disease. It is not as yet known, however if B.O.P. represents disease activity⁹.

2) The degree of penetration of the probe varies with increased probing force⁶ and there exists significant variability used between operators and between different areas in the mouth.

3) In health the probe tip will approximate the apical end of the epithelial attachment¹⁰ however in the presence of inflammation the probe will penetrate into the connective tissue¹⁰.

4) Following periodontal treatment the probe tip will likely rest within a "long junctional epithelium" due to the increased tissue resistance.

Conclusions on probing

Clinical probing is an unacceptable means of accurately measuring the connective tissue level before and especially after treatment. Probing as well, or bleeding upon probing is not an indicator of disease activity but rather a record of past clinical attachment loss. This parameter however is still our most accurate and valuable diagnostic instrument in monitoring the patient's periodontal status.

2) Tooth mobility — Malocclusion

The periodontal examination should include an occlusal and mobility analysis. Readers are referred to the October 1985 *Oral Health* issue, page 18, Figure 4, for an example of the components of an occlusal analysis as could be printed on your assessment form. The mobility of each tooth should also be assessed and recorded using a mobility classification as follows:

CLASS I — slightly greater than normal

CLASS II — significantly greater than normal and approaching 1 mm in any direction

CLASS III — greater than 1 mm and/or depressible

One can denote an inbetween mobility of eg. "I½" as "I+".

When properly assessed, mobility can often be a fairly good prognostic indicator. It is important to remember to luxate the tooth firmly with two rigid instruments (eg. two mirror handles). Although there may be interexaminer variability on what constitutes a Class I, II or III, it is more important that there be minimal intra-patient variability. As long as there is a consistency between the various time periods of the mobility measurements, there will be an added significance to any changes that are seen over time.

The role of malocclusion and significance of tooth

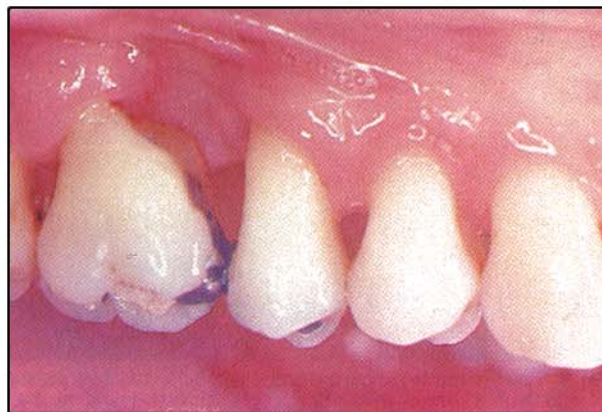

Fig. 4. Mesio-buccal root amputation.

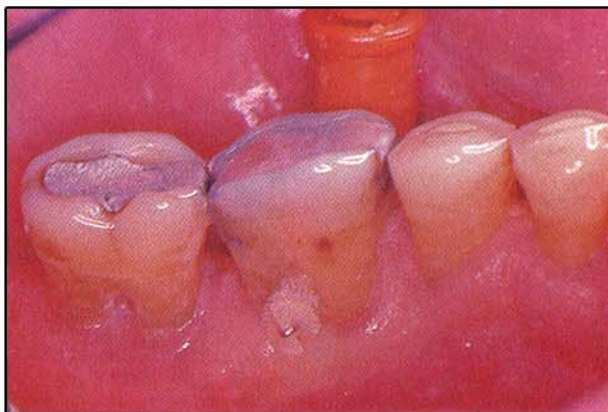


Fig. 5. Post surgically — the "barrelling" open of the furcation allows the passage of the proxa brush.

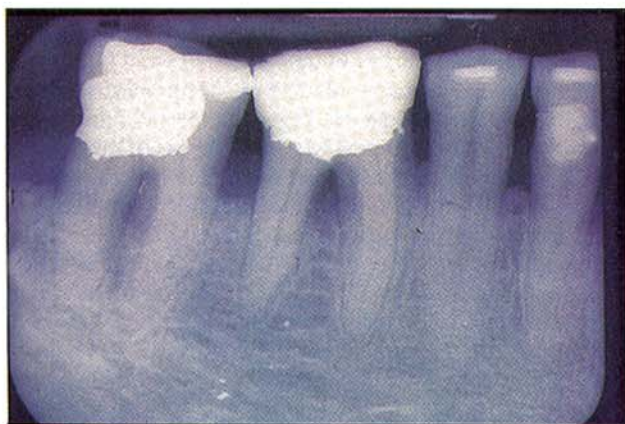


Fig. 6. Class III furcation of molar in Fig. 5.

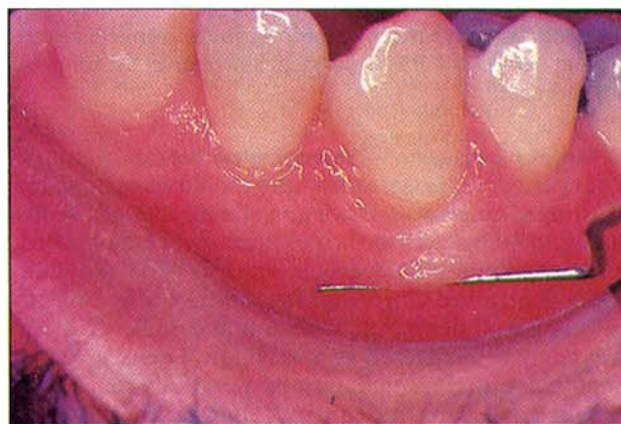


Fig. 7. The "roll test" to delineate the muco-gingival junction.

mobility are two controversial subjects that have been recently undergoing scientific examination. The results have led to some significant changes in the philosophy of treatment amongst many practitioners. Although it is not possible to go into great detail, it is worthwhile to outline some of the highlights, concerning mobility and malocclusion as they relate to periodontal disease.

The effects of malocclusion with resultant tooth mobility have recently been more carefully studied in animal model experiments²². The data is voluminous but the experimental results have allowed us to extrapolate some clinical treatment guidelines as follows:

- A) When considering occlusal treatment
 - 1) control inflammation first, then
 - 2) consider occlusal adjustment if
 - i) the residual mobility is incommensurate with the attachment level;
 - ii) fremitus and mobility coincide (fremitus is the movement pattern of teeth as they are displaced during the various excursions)
 - 3) consider splinting if after inflammation is controlled:
 - i) there is a continually increasing mobility
 - ii) to accommodate the patient's needs for comfort and/or function.

3) Furcation involvement

Utilizing a "pigtail" or #23 type of explorer, examine and record all existing furcation involvements on your periodontal assessment form. Furcations are graded as I, II or III using the following guidelines:

Grade I: horizontal penetration of less than 3 mm
 Grade II: horizontal penetration greater than 3 mm but not a "through and through" furcation communication

Grade III: "through and through" furcation communication

Your periodontal assessment form should be designed

with sufficient space in order to accommodate the grades of all furcation involvements, namely the buccal and lingual on the mandibular molars, mesial and distal on the maxillary first bicusps and buccal, mesial and distal on the maxillary molars.

In determining the prognosis of a multi-rooted tooth, furcation involvement plays a very important role, however opinions have varied as to their relative importance. As well, the suggested methods of treatment for teeth with furcations have ranged from extraction, root removal (Fig. 4), surgery exposing the furcation (Fig. 5, 6), to conservative treatment¹⁹. The particular choice of treatment of course is dependant on many factors² such as the severity of the furcation, residual attachment, root anatomy, how strategic the involved tooth is in the overall treatment plan, patient age and economic situation just to name a few. It is not within the scope of this article to go into all the detailed considerations involved in furcation management. However some relatively recent long-term studies^{5,11,19} have revealed some interesting findings such as:

A) Conservatively treated (non-surgical) and even untreated teeth with furcations did not fare quite as poorly over a long-term period (statistically speaking) as what would have been thought by some¹³. In spite of this finding however, furcation involvement was a definite indication of a poorer survival rate as compared to teeth without a furcation.

B) The prognosis of furcated teeth with root amputation appears to be good if there is adequate plaque control, adequate residual support and stability and if the endodontic, occlusal and restorative procedures are properly done^{4,11,19,16,21}.

It is impossible to give exact guidelines for the management of furcations as each case must be evaluated on its own merit. Although some furcations can be conservatively maintained, the anatomical complications carry a significant negative influence on

the prognosis. In certain situations, in the opinion of the author, more advanced surgical corrective techniques are indicated.

4) Gingival recession — Mucogingival defects

Your periodontal assessment form should accommodate charting of gingival recessions on all oral and facial root surfaces. In this way suspicious areas can be monitored for any “continuing” recession. The lack of an adequate width of attached gingiva is often intimately associated with areas of significant recession and some of these areas may be diagnosed as mucogingival defects. Some important questions that must be answered are: a) how do you define “attached gingiva”? b) what constitutes a mucogingival defect? c) how much attached gingiva is adequate? and d) when should mucogingival surgery be done?

a) **How do you define “attached gingiva”?** — As the name implies it is gingiva that is attached to the root surface via Sharpey’s fibres. In the clinical sense however, it also indicates an attached gingival tissue that demonstrates keratinization. In this article this is what I will mean by the term “attached gingiva”. One can “estimate” the width of the “attached gingiva” by measuring the distance from the free gingival margin to the mucogingival junction (MGJ) and then subtracting the pocket depth. I emphasize the word “estimate” because the MGJ and the pocket depth cannot be precisely measured. In cases where the mucogingival junction is relatively indistinct, the “roll test” can be used where the flat end of an instrument is placed firmly in the mucosa and drawn coronally (Fig. 7). The location of the immobile tissue will approximate the mucogingival junction. Readers are referred to the section in this article on probing, for more details on the inherent inaccuracies of this diagnostic tool in identifying the histological pocket depth.

b) **What constitutes a mucogingival defect?** — In the past some of the classical signs of what were considered to be mucogingival problems were: i) “inadequate” attached gingiva (non-specific); ii) pockets extending beyond the mucogingival junction; iii) significant gingival recession; iv) presence of gingival clefts.

Some classical indications for mucogingival correction are: i) prior to orthodontic labial tooth movement; ii) prior to subgingival crown margin placement where there is insufficient attached gingiva; iii) where there exists a shallow vestibule and/or frenal attachments, such that moving the lips and cheeks cause blanching or displacement of the gingival margin.

c) **How much attached gingiva is adequate and when should mucogingival surgery be done?** — There have been very few experiments studying this important question. Lang and Loe¹² suggested 2 mm of keratinized gingiva corresponding to 1 mm of attached gingiva was necessary to maintain the gingiva healthy and inflammation free. However, Dorfman et al⁷ found that over a four-year period, there were no signs of attachment loss in 42 patients with bilateral areas of inadequate attached gingiva. This was the case where the patients demon-

strated excellent home care and only had mucogingival surgery unilaterally.

In summary most of the scientific information available would seem to suggest that in many cases gingival health can be maintained in areas of minimal or no keratinized gingiva. However in the clinical setting, the adequacy of the width of attached gingiva and therefore the potential need for surgical correction depends on the individual situation. Some important factors that must be considered are: a) evidence of “continuing” recession, b) strategic nature of the tooth involved, c) patient age, d) sensitivity, e) esthetic complaints, f) level of home care, g) other dental requirements such as labial orthodontic tooth movement or placement of subgingival crown margins. One could attempt to summarize today’s indications for mucogingival surgery as when there is inadequate attached gingiva to 1) maintain the area inflammation free, 2) maintain patient comfort and/or esthetics to their satisfaction, 3) certain cases where orthodontic and/or prosthetic treatment is to be under-taken, 4) certain mucogingival defects in children.

PERIODONTAL CONSULTATION

With all consultations there is an important psychological component that should be recognized. Although it is not my intention to go into great detail on this particular aspect of the consultation, some points deserve mention.

- 1) When presenting the outline of treatment, do so in a confident, but not an arrogant manner. Showing the patient that you care and have an understanding attitude goes a long way in helping to communicate effectively.
- 2) Avoid the technical terminology! Customize the consultation to a level that the individual can comprehend.
- 3) Don’t hurry, and always be more than willing to answer all your patients’ questions.

Successful periodontal therapy relies heavily on your patient’s commitment. This can best be achieved once your patient has an adequate understanding of the disease process and your recommended treatment. Your ability to effectively inform and communicate during the “consultation” are the key beginnings to successful therapy. The discipline of periodontics in particular lends itself well to getting the patient involved in the consultation. The dentist should give the patient a large mirror and then in the patient’s own mouth demonstrate signs of disease such as plaque, calculus, suppuration, gingival inflammation, recession, mobility, and pocket depth. It is helpful to use other aids such as radiographs, study models, photos, videotapes, and written material. In this article I would like to go into some detail about four adjuncts that I incorporate in my consultation. These are the: 1) consultation check list, 2) photo album, 3) patient information binder and 4) treatment plan/insurance estimate form.

I The consultation checklist A "check-list" of all the points that need to be covered in the consultation can be typed up and photocopied on a single side of paper 8½" × 11". Serving a dual function of being a reminder to the dentist as well as a pseudo-contract, it can be signed at the bottom by the patient and dentist. My check-list is an abbreviated form of what follows:

THE CONSULTATION CHECK-LIST (POINTS TO COVER)

1. SEVERITY OF THE PATIENT'S PERIODONTAL CONDITION
2. ETIOLOGY OF PERIODONTAL DISEASE(S)
3. SUGGESTED TREATMENT PLAN
4. ALTERNATIVE TREATMENT PLANS (COMPROMISES)
5. EXPECTED BENEFIT OF TREATMENT
6. PROGNOSIS WITHOUT TREATMENT
7. IMPORTANCE OF HOME CARE
8. IMPORTANCE OF COMPLIANCE WITH MAINTENANCE CARE
9. POSSIBLE SIDE EFFECTS OF TREATMENT (SURGICAL AND NON-SURGICAL)
 - A) RECESSION
 - B) SENSITIVITY
 - C) FOOD IMPACTION
 - D) ESTHETICS
 - E) PHONETICS
 - F) MOBILITY
 - G) PARASTHESIA
10. CARE REQUIRED IN ADDITION TO PERIODONTAL
11. SOME TREATMENTS TO BE DONE BY QUALIFIED AUXILIARY STAFF.

IT IS ALSO USEFUL TO INCLUDE THE FOLLOWING:

12. PROMPTNESS FOR APPOINTMENTS
13. ADEQUATE CANCELLATION NOTICE
14. FINANCIAL ARRANGEMENTS
15. RECORDS REMAIN THE PROPERTY OF THE DENTIST
16. RECORDS CAN BE USED FOR EDUCATIONAL PURPOSES
17. CONSENT GIVEN TO CONSULT WITH M.D. AND D.D.S. AS NEEDED

PATIENT'S SIGNATURE _____

DDS SIGNATURE _____

II Photo album

"A picture is worth a thousand words" was never so true when trying to explain something about dental treatment to the layperson. Having a photo album handy during your consultation is a tremendous aid in communicating with your patient. Sufficient copies should be available to leave one in each room. I keep my "clinical camera set-up" close by and thus I have been able to produce a comprehensive photo album from my own clinical material. If this is not convenient for you there are photo albums that can be purchased. Of course the material need not be limited to the field of periodontics. As an example, however, I have listed the subject matter in my album.

Photo album

Plaque accumulation	Amalgam overhang
Calculus accumulation	corrected
Subgingival deposits	Pathological tooth
Microscopic view of plaque	migration
Amalgam overhang	Malocclusion

Periodontal probing
 Radiographs: Peri-Apical vs
 BiteWing
 Mobility
 Furcation
 Recessions
 Inflammation
 All various oral hygiene
 aids
 Subgingival scaling
 Scaling-tissue response
 Gingivectomy
 Flap
 Osseous resection

Surgical crown lengthening
 Osseous grafts
 Soft tissue grafts
 Root amputation
 Strategic extraction
 Orthodontics
 Endodontics
 Prosthetics-interim
 Prosthetics-removable
 Prosthetics-fixed
 Occlusal adjustment
 Bit plates
 Dental implants

III Patient information binder

An excellent way to be thorough in your consultation with your patient and yet avoid "information overload" is to give out some appropriate material in writing. In this way the patient can read over the hand-outs at their leisure thereby refreshing their memory and reinforcing your consultation message. You can prepare a list of topics and then write up an explanation on each one, (but not in too great detail) so that it will fit onto one side of an 8½" × 11" sheet of paper. After running off photocopies, put it all together in an indexed 3-ring binder. (One binder in each room). For eg., here is a list of the hand-outs available at our office;

- 1) New patient welcome-office policies
- 2) Financial and insurance arrangements
- 3) Radiographs – indications and safety
- 4) Consultation check list
- 5) Treatment plan/insurance estimate form
- 6) Chronic adult periodontics
- 7) Pregnancy gingivitis
- 8) Juvenile periodontitis
- 9) Mucogingival defects
- 10) Trench mouth (A.N.U.G.)
- 11) Dilantin hyperplasia
- 12) Malocclusion-occlusal adjustment
- 13) T.M.J.
- 14) Bite guards
- 15) Home care-oral hygiene
- 16) Post-surgical home care
- 17) Periodontal maintenance therapy
- 18) Keyes technique
- 19) Patient comfort techniques
- 20) Systemic resistance

IV Treatment plan/insurance estimate form

With slight modifications, a standard ODA insurance estimate form can serve the dual function of being a treatment plan. This is done in a format that is easy to comprehend for both the patient and any staff person. This form should be filled out in duplicate during every consultation. If the patient wishes, their copy can serve as an insurance pre-authorization or they can keep it in their possession as a guide to the upcoming appointment procedure and fee. The other copy is kept in the patient's file and functions as an excellent treatment plan form. Below is an example of the modifications in use at our office. (I have very rarely received complaints from insurance companies concerning the modified format).

Perio. Treatment Plan Chart

(INSERT DOCTOR'S NAME, ADDRESS, ETC)
(CAN USE LETTERHEAD)

PERIODONTAL TREATMENT PLAN FOR _____

This section to be completed by Patient

S
U
B
S
C
R
I
B
E
R

Name _____

Address _____

Employer _____

Address _____

GROUP POLICY

CERTIFICATE
NO.

SOC. INS. NO.

PATIENT'S DATE OF BIRTH

RELATIONSHIP TO SUBSCRIBER

This estimate valid for
4 months commencing _____

**SERVICES AND FEES MAY VARY DURING
TREATMENT DUE TO UNFORSEEN FACTORS**

APPTS.	TREATMENT PLAN	UNITS	FEE
	Clinical Examination 01400	_____	_____
	Oral Hygiene Instruction 13200	_____	_____
	Radiographs 02100/02910	_____	_____
	Consultation/Treatment Plan 05200	_____	_____
	Diagnostic Models _____	_____	_____
	Oral Hygiene Re-instruction _____	_____	_____
	Scaling/Root Planing 43400	_____	_____
	Scaling/Root Planing 43400	_____	_____
	Scaling/Root Planing 43400	_____	_____
	Scaling/Root Planing 43400	_____	_____
	Occlusal Adjustment 43310	_____	_____
	Re-examination — Report II after 1-2 months 01400	_____	_____
	Other _____	_____	_____
	Periodontal Surgery:		
	_____ sites of type 42100-OSSEOUS	_____	/per site
	_____ sites of type _____	_____	_____
	_____ sites of type _____	_____	_____
	Post-surgical Treatment 42500	_____	_____
	1-2 months after surgery	_____	_____

Estimated total: _____

Signature of Periodontist _____

1. Aeppli, D.M. et al., "Measuring and Interpreting Increases in Probing Depth and Attachment Loss", *Journal of Periodontal* #5, pg. 262, 1985.
2. Arlin, M.L., "Strategic Extractions. Periodontal and Restorative Considerations", *Oral Health*, Vol. 73 #10, pg. 15, 1982.
3. Arlin, M.L., "Periodontal Assessment Forms", *Oral Health*, October 1985, Vol. 75 #10, pg. 17.
4. Bergholtz A., "Radectomy of Multirrooted Teeth", *J.A.D.A.* 85:87, 1972.
5. Bjorn Al and Hjort, "Bone loss of Furcated Mandibular Molars. A longitudinal Study.", *Journal of Clinical Perio.* Vol. 9, pg. 402, 1982.
6. Chamberlain, ADH et al., "Significance of Probing Force for Evaluation of Healing Following Periodontal Therapy", *Journal of Clin. Periodontal.*, V. 12, pg. 306, 1985.
7. Dorfman et al., "Longitudinal Evaluation of Free autogenous gingival Grafts. A 4 year Report", *Journal of Periodontal.*, Vol. 53, pg. 349, 1982.
8. Freed, H.K. et al., "Evaluation of Probing Forces", *Journal of Periodontal* #8, pg. 488, 1983.
9. Greenstein G., "The Role of Bleeding Upon Probing in the Diagnosis of Periodontal Disease — A Literature Review", *Journal of Periodontal*, Dec. 1984, pg. 684.
10. Hancock, E.B. and Wirthlin, M.R., "The Location of the Periodontal Probe Tip in Health and Disease", *J. Period.* 52:124, 1981.
11. Hirschfeld, L. and Wasserman, "A long term survey of tooth loss in 600 Treated Periodontal Patients", *J. Periodont.* 49:225-237, 1978.
12. Lang, N.P. and Loe H., "The Relationship Between the Width of Keratinized Gingiva and Gingival Health", *Journal of Periodont.* Vol. 43, pg. 623, 1972.
13. Leonard, H.J., "Indications for the Removal of Teeth from the Standpoint of Oral Diagnosis and the Periodontia", *Dental Cosmos*, 73:pg. 390, 1931.
14. Listgarten, M.A., "Changing Concepts about the Dentogingival Epithelial Junction", *J. Canada Dent. Assn.* 36:70, 1970.
15. Listgarten, M.A., "Normal Development, structure, physiology, and repair of gingival epithelium", *Oral Sciences Reviews* 1:3, 1972.
16. Nyman S. and Lindhe, "Considerations in the treatment of patients with Multiple Teeth Furcation involvements", *Journal of Clinical Periodont.*, Vol. 3, pg. 4, 1976.
17. Page, R.C. and Schroeder, H.E., "Pathogenesis of Inflammatory Periodontal Disease", *A Summary of Current Work, Lab. Invest.*, 33:235, 1976.
18. Robinson, P.J. and Vitek, R.M., "The relationship between Gingival Inflammation and Resistance to Probe penetration", *J. Periodont. Res.* 14:239, 1979.
19. Ross, I.F. and Thompson, R.H., "Furcation Involvement in Maxillary and Mandibular Molars", *Journal of Periodont.* Vol. 51, pg. 450, 1978.
20. Spray, J.R. and Garnick, J.J., "Position of Probes in Human Periodontal Pockets", *Jr. Dent. Res.* 58:176, 1978.
21. Waerhaug, J., "The Furcation Problem, Etiology, Pathogenesis, Diagnosis, Therapy and Prognosis", *J. Clin. Perio.* 7:73, 1980.
22. Zander, H., "Occlusion and Occlusal Therapy in Periodontitis", *Journal of Periodont.* Vol. 48, pg. 540, 1977.