

Periodontal diseases

A differential diagnosis

Leonard Schwartz, BSc, DDS

Murray L. Arlin, DDS, FRCD(C)

Diagnosis is the art of distinguishing one disease from another. Today more than ever, the practicing dentist must not only be responsible for his therapeutic procedures but must also be able to defend his diagnoses. With the recent explosion of knowledge from research in the field of periodontology, there have been many important changes in concepts of periodontal diagnosis and treatment. What was taught in dental school 10 years ago may not apply in light of more recent knowledge.

Periodontal diagnosis demands as an essential pre-requisite, a comprehensive periodontal examination recorded on suitable assessment forms^{1,2}. The diagnosis is based on an analysis of the case history, clinical examination, radiographic examination and laboratory tests. It is critically important that the clinician have sufficient knowledge to establish a differential diagnosis and thus be able to ultimately establish the one definitive and correct diagnosis. It is not within the scope of this article to provide detailed information on diagnostic procedures as a whole but rather to selectively address the diagnosis of the periodontal diseases. For further information, interested readers should refer to Lindhe's recent textbook of periodontology³.

There are several forms of periodontal disease (Tables 1 and 2) and it is critical to correctly diagnose the "case" in order to anticipate a successful result. Periodontology is scientifically based perhaps more than any other dental discipline, and recent research has given rise to specific clinical therapies that are dependent on the type of periodontal disease being treated.

One can broadly classify periodontal diseases into gingivitis and periodontitis. The pathogenesis of the relationship between these two disease states is still somewhat obscure and continues to be vigorously investigated. We do know that gingivitis does not invariably lead to periodontitis (Fig. 1, 2). As well, periodontitis is only sometimes associated with obvious clinical gingivitis (Fig. 3, 4). These phenomena underly

the importance of periodontal probing as the clinician can be fooled by healthy looking gingiva (Fig. 5, 6).

Chronic gingivitis is the most common form of gingival disease (Fig. 1). Signs and symptoms include gingi-

Table 1 — Gingival disease

A: Chronic

1. early
2. moderate
3. severe
4. gingival enlargement
 - a) plaque-induced
 - b) drug-induced
 - c) hormone-induced

B: Acute

1. acute necrotizing ulcerative gingivitis (ANUG)
2. acute herpetic gingivostomatitis (AHGS)
3. desquamative gingivitis
4. pericoronitis

val bleeding as well as changes in colour, surface texture and shape of the marginal gingiva. Usually, gingivitis develops gradually and its distribution may be classified

Dr. Schwartz has a private practice in periodontics in Markham, Ont. Dr. Arlin's private practice in periodontics is in Weston, Ont.

We are pleased to present the first publication of their article written specially for Oral Health.

as localized, generalized, marginal or diffuse. Chronic gingivitis is primarily plaque induced, is rarely painless and is usually reversible when proper oral hygiene measures are instituted.

Gingival enlargement is not so much a separate disease entity but rather a common feature of gingival disease.

TABLE 2 — Periodontitis

A. Acute

1. periodontal abscess
2. lateral periodontal cyst
3. endodontic — periodontal lesions

B. Chronic

1. prepubertal
2. juvenile, localized
3. juvenile, generalized
4. adult rapidly progressive
5. adult chronic (early-moderate-advanced)

There are many different forms of enlargement that can be classified based on the etiological factors as well as the distribution of the enlargement. Inflammatory, pregnancy (Fig. 2) and phenytoin induced enlargement are three common forms. The enlargement may be localized, generalized, marginal or diffuse.

TABLE 3

ANUG (Fig. 7)

1. etiology not completely established
2. necrotizing condition
3. pseudomembrane
4. punched out interdental papilla
5. marginal gingiva affected
6. uncommon in children
7. indefinite duration
8. not contagious

AHGS (Fig. 8)

1. herpes simplex viral etiology
2. vesicle formation
3. diffuse erythema
4. vesicle rupture forms round ulcers
5. more diffuse involvement
6. common in children
7. 7-10 days duration
8. contagious

Acute gingival infections that are commonly encountered in the dental office include: a. acute necrotizing ulcerative gingivitis (ANUG) (Fig. 7); b. acute herpetic gingivostomatitis (AHGS) (Fig. 8); c. desquamative gingivitis (Fig. 9); d. pericoronitis (Fig. 10). The symptoms of ANUG include pain, foul taste, lymphadenopathy and temperature elevation. AHGS is also characterized by pain, general malaise and high fever. Table 3 contrasts these two acute gingival conditions.

Desquamative gingivitis (Fig. 9) is not actually a diagnosis but a description term indicating a "peeling off" of the surface of the gingiva and/or mucosa. It is important to establish the underlying etiology of the desquamation which will often necessitate an immunofluorescent gingival biopsy. Possibilities for a differential diagnosis include food or chemical burn, allergy, pemphigus or pemphigoid.

Pericoronitis (Fig. 10) is a term that refers to the inflammation of the gingiva in relation to the crown of a tooth that most commonly is an incompletely erupted mandibular molar. The signs and symptoms include pain, redness and swelling that is often accompanied by lymphadenopathy and malaise.

The periodontal abscess (Figs. 11, 12) is a localized purulent inflammation that most commonly arises from: a. the inner aspect of the soft tissue pocket wall; b. in a cul-de-sac pocket that may form a tortuous course around the root; c. an inadequately treated pocket where superficial gingival shrinkage occurs while subgingival root deposits are left.

Under these three conditions, acute exacerbation of a chronic periodontal problem will arise when there is continued pus formation concomitant with inadequate drainage. These acute lesions will generally subside and persist in the chronic state. In the acute stage, the patient will have symptoms of pain, tooth mobility and sometimes lymphadenopathy, however, the chronic state may be asymptomatic. As abscess formation is often accompanied by irreversible rapid alveolar bone loss, (Fig. 11, 12) it is important that emergency treatment be instituted.

If an acute periodontal abscess is adequately treated at an early stage, there may be a greatly enhanced regenerative potential (as compared to chronic attachment loss). Clinically, the acute abscess is characterized by a swollen gingiva that may be firm or may exude pus. There is often a sinus tract extending from the bone loss region out through the oral mucosa. The radiographic appearance is variable depending on the location, (i.e., radicular or interproximal) and the extent of the bone loss. In some cases, there is a definite radiolucency on the lateral aspect of the root but one cannot rely exclusively upon the radiograph for a diagnosis. Rather the diagnosis is made by correlating the dental history, clinical and radiographic signs.

The lateral periodontal cyst strictly speaking is a developmental cyst of odontogenic origin which is located along the lateral aspect of the root(s). When observable clinically, it presents as an immovable mass, with normal overlying mucosa often in the mandibular canine-bicuspid region. Histologically, the lesions have at times been found to be odontogenic keratocysts⁶. In other cases, a laterally occurring cyst may be associated with a pulpal canal and thus be of endodontic origin. Another possibility with cases of advanced periodontal

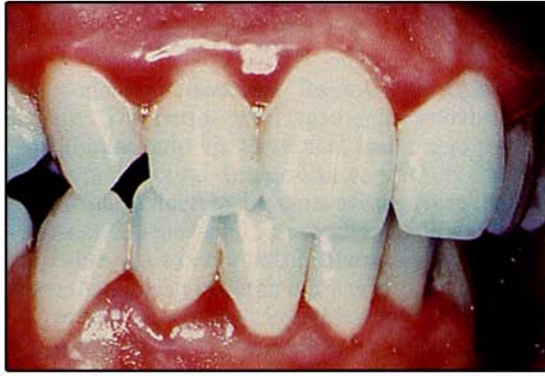


Fig. 1 — Early gingivitis: Inflammation in the gingiva is similar to inflammatory lesions in other tissues. The body's reaction results in vascular dilation, proliferation and increased permeability. The clinical alterations are characterized by gingival redness, swelling, loss of stippling and bleeding.

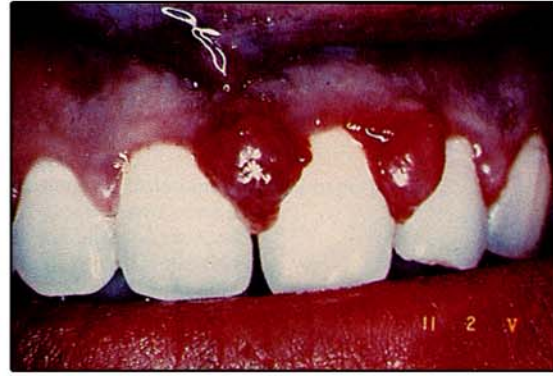

Fig. 2 — Pregnancy gingivitis: Hormonal changes during pregnancy may exaggerate the gingival inflammatory response due to an alteration in tissue metabolism. Clinically, the gingiva is usually fiery red with enlargement of the interdental papillae which bleeds easily and can be painful.

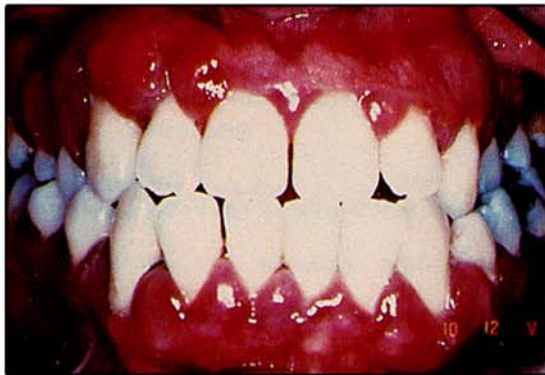

Fig. 3 — Advanced gingivitis and periodontitis: Untreated gingivitis usually will progress to attachment loss. In the absence of professional treatment and home care, there is often a concomitant gingivitis and periodontitis in the periodontally susceptible patient.

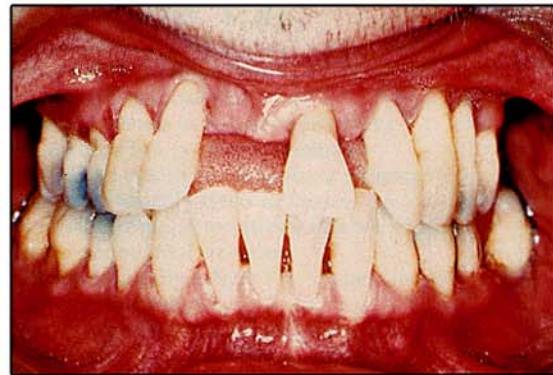

Fig. 4 — Advanced periodontitis: Certain patients exhibit advanced periodontitis without any obvious signs of clinical gingivitis. Sometimes this is because treatment may have only resolved the soft tissue lesion. In other cases, a minority of patients classified as very susceptible or downhill may continue to loose bone even though there seems to be minimal or no gingival inflammation.

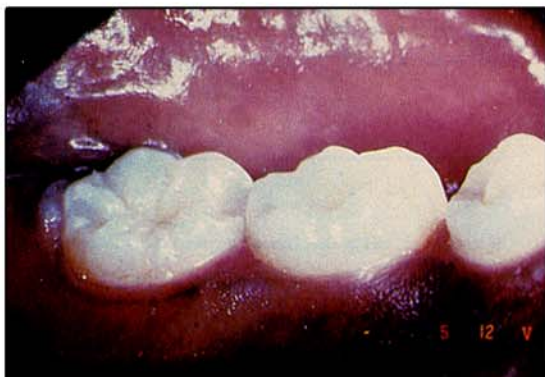

Fig. 5 — Apparent gingival health: From a visual examination alone, the clinician would suspect this periodontium to be healthy in this 14 year old black female (see Fig. 6).

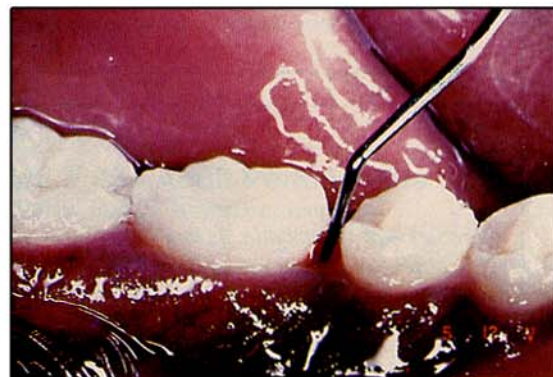


Fig. 6 — Localized juvenile periodontitis: With a careful examination including periodontal probing, what appears to be periodontal health (see Fig. 5) turns out to be localized advanced bone loss characteristic of juvenile periodontitis.

disease is that pocket epithelium becomes entrapped and gives rise to a cyst in the pocket wall.

Combined endodontic-periodontic lesions can cause acute symptoms. The periodontal ligament communicates with the dental pulp via the apical and accessory canals and thus periodontal disease-like conditions can be initiated and maintained by irritants arising from the root canal system. Lesions can be broadly classified in five groups (Table 4). It is not within the scope of this article to cover this subject in detail but it is important to establish a proper diagnosis in order to prevent unnecessary treatment. Root fractures and root perforations as a complication of endodontic treatment must also be considered in the differential diagnosis.

The features of the various chronic forms of periodontitis are presented in Tables 5, 6, 7 and 8 and are reproduced in part from a recent article in *Oral Health*⁴.

Today the evidence indicates that the term Periodontal Disease actually comprises a group of different disorders that affect the periodontium. In this article,

TABLE 4 — Periodontic — Endodontic lesions

1. primary periodontal
2. primary endodontic
3. primary periodontal with secondary endodontic involvement
4. primary endodontic with secondary periodontal involvement
5. true combined periodontal endodontic lesion.

only those conditions that are primarily of a microbial etiology have been discussed. Other conditions such as trauma from occlusion, manifestation of systemic disorders in the periodontium and tumour related lesions have not been addressed. From the information presented, it should be obvious that the signs and symptoms of the different forms of periodontal disease vary considerably and the clinician must be astute to arrive at a proper diagnosis. Although not covered in this article, the treatment as well is varied and must be customized to the particular form of disease and the individual patient.

Bibliography

1. Arlin, M. L., "Periodontal Assessment Forms" in *Oral Health*, Volume 75, October 1985, Page 11
2. Arlin, M. L., "Periodontal Examination and Consultation" in *Oral Health*, Volume 76, January 1986, Page 37
3. Lindhe, J., "Textbook of Clinical Periodontology" 1984 First Edition Munksgaard, Copenhagen
4. Joseph, C. E., and Faroush, A., "Current Concepts of Periodontitis" in *Oral Health*, Volume 75, October 1985, Page 33
5. Shafer, W. G., Hine, M. K., and Levy, B. M., "A Textbook of Oral Pathology" Edition 33, Pages 243-245, Philadelphia, W. B. Saunders Company 1974
6. Cohen, D. A., et al., "The Lateral Periodontal Cyst — A Report of 37 Cases" in *Journal of Periodontology*, Volume 55, No. 4, pages 230-234, April 1984

TABLE 5 — Prepubertal Periodontitis

- onset with primary dentition
- rare prevalence
- possibly genetic etiology
- generalized form:
 - acute gingival inflammation and hyperplasia
 - rapid gingival and bone loss
 - deficient immune response
 - resistant to antibiotic therapy
 - all primary dentition affected
 - permanent dentition may be affected
- localized form:
 - not all primary teeth affected
 - minimal or no inflammation and hyperplasia
 - less rapid tissue loss
 - less severe immuno-deficiency
 - responsive to therapy.

TABLE 6 — Juvenile Periodontitis (Figs. 5, 6)

- pubertal onset
- minimal clinical inflammation
- minimal plaque and calculus
- increased prevalence in females and blacks
- familial distribution (x-linked dominant)
- immunodeficiencies in neutrophils or monocytes
- disease activity usually slows or ceases
- lesions usually respond to tetracycline when combined with periodontal treatment
- localized form usually affects first molars and/or incisors (symmetrically)
- generalized form affects most if not the entire permanent dentition.

TABLE 7 — Adult rapidly progressive

- age of onset between puberty to 35 years
- most teeth affected
- most patients had juvenile periodontitis
- after rapid attachment loss, disease activity may slow or cease
- most patients exhibit immunodeficiency
- some patients respond to periodontal treatment.

TABLE 8 — Adult Periodontitis

- age of onset usually 30 years or more
- usually many teeth exhibit attachment loss but variable progression is cyclical but usually not rapid
- patients do not exhibit immunodeficiencies
- an acute periodontal abscess is not a common feature unless the attachment loss is more advanced
- antibiotic therapy alone is ineffective as a long term treatment
- often there are few or no clinical symptoms.

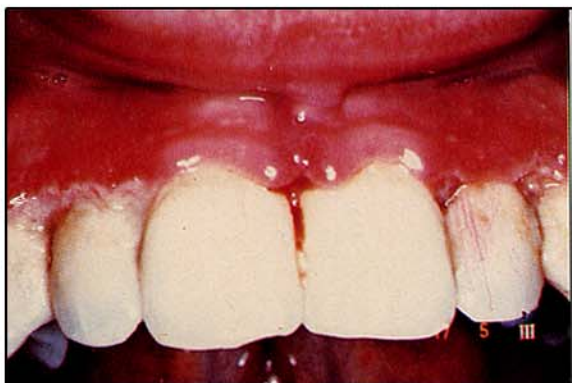

Fig. 7 — Acute necrotizing ulcerative gingivitis (ANUG): With ANUG in its most common form, there are interproximal necrotic ulcers covered with a greyish membrane. The lesions are extremely painful and easily bleed. Also called Trench Mouth and Vincent's Infection, the etiology of this condition may be at least partially due to stress.

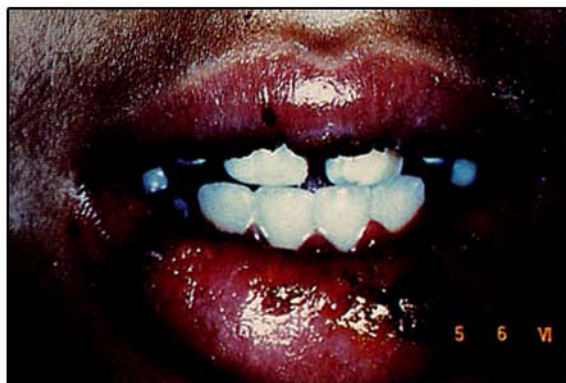

Fig. 8 — Acute herpetic gingivostomatitis (AHGS): In contrast to ANUG, there are no definite intraoral predilection sites. Lesions are most commonly seen on the lips, tongue and buccal mucosa. The lesions initially present as small round greyish vesicles which break leaving small ulcers and diffuse erythema.

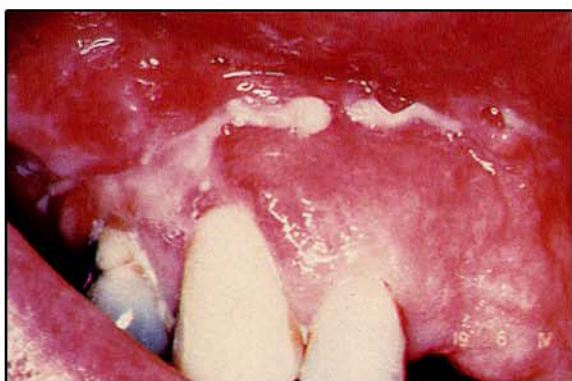

Fig. 9 — Desquamative gingivitis: This descriptive term indicating a "peeling off" of the gingiva or mucosa does not constitute a diagnosis. The differential diagnosis includes many possibilities including pemphigus which can be fatal. When there is a possibility of this disorder, the clinician should arrange that the patient undergo an immunofluorescent biopsy. Conventional biopsy medium is inappropriate in this situation.

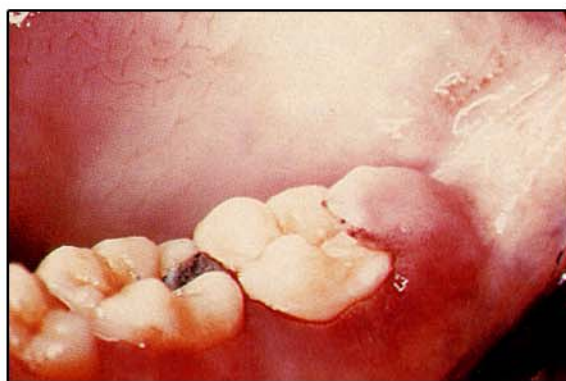


Fig. 10 — Pericoronitis: this patient exhibits a pericoronitis on the distal of the mandibular second molar after initial periodontal therapy has resolved most of the acute inflammation. At this stage, the tissue can now be excised. More commonly, the patient initially presents with the tissue acutely inflamed and in the third molar region.

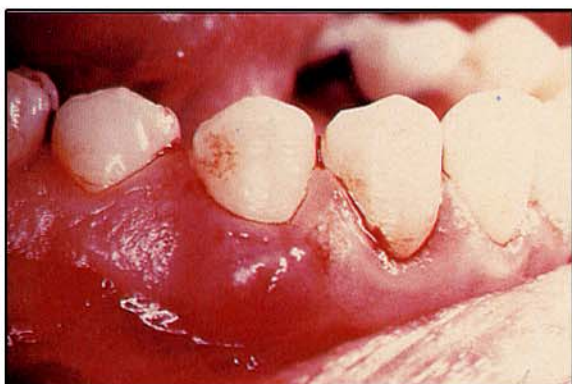

Fig. 11 — Acute periodontal abscess: The clinical and radiographic signs and symptoms vary considerably. Whereas often patients will present to the office on an emergency basis, there can be some patients who are totally unaware of the lesion. (same patient as in Fig. 12)

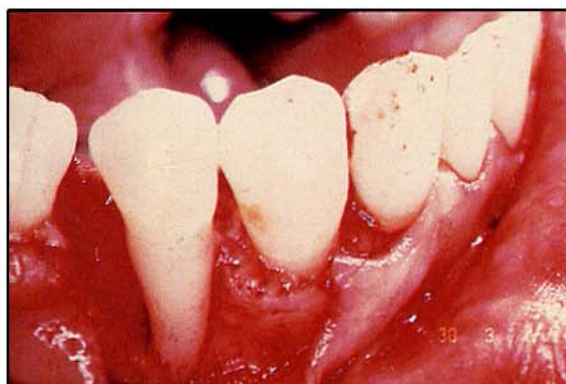

Fig. 12 — Acute periodontal abscess: The rate of destruction can be very aggressive. This particular patient did not exhibit any clinical or radiographic attachment loss 3 months previously. (same patient as in Fig. 11)