

Furcations

Their management

M. Arlin, DDS, Dip. Period., FRCD(C)

Due to anatomical limitations, furcations often prevent adequate plaque control which may eventually result in tooth loss¹. Treatment has been developed that may provide the option of tooth retention when previously, extraction was the only definitive approach.

Furcation invasion can be observed in molar and premolar teeth in both the horizontal and vertical dimensions. The following classification is a suggested guide for aid in diagnosis (see Table I).²

Definitions

Frequently, tooth resection is used to treat furcation invasions and thereby improve the long-term prognosis of affected teeth. There continues to be some lack of consistency with regards to tooth resection terminology and so the following definitions are suggested:

a. Tooth resection

Tooth resection indicates the excision of any segment of the tooth and/or root.

b. Root amputation

Root amputation indicates the removal of a root but without removal of the overlying associated crown portion.

c. Hemisection

Hemisection refers to the removal of half of the clinical crown with associated root(s). This would apply to the mesio-distal sectioning of a maxillary molar or buccolingual sectioning of a mandibular molar followed by removal of one of the halves.

d. Root separation (bicuspidization)

Root separation denotes splitting of a mandibular molar with retention of both sections.

e. Trisection

Trisection of a maxillary molar denotes the splitting of the tooth (independent of whether the separated portions are retained or not).

Evaluation of therapy

Several retrospective long-term studies have indicated that the prognosis of "maintained" non-resected teeth with furcation involvement, may not be as poor as once thought.^{3,4,5} Therefore, when one considers the morbidity, time and cost involved in tooth resection procedures, a conservative approach should be considered unless

there are strong indications for a tooth resection. Noteworthy in this regard is a study by Langer, Stein and Wagenberg.⁶ A random sample of 100 patients treated with root resections were evaluated after a 10 year period. A total of 38 teeth failed but only 15.8% of these occurred within the first five years after surgery. Interestingly only 26.3% of the failures were as a result of periodontal breakdown. Some other common causes of tooth loss were root fractures, endodontic complications and undermining caries.

Etiology

Furcation involvements are most commonly caused by plaque-induced periodontitis. Predisposing factors (anatomical or iatrogenic) include those which enhance plaque accumulation and/or prevent oral hygiene efforts. Some predisposing factors which are commonly observed include:

a. Furcation anatomy

i. Proximity to the CEJ is significant in that the more coronally positioned the furcation, the less periodontal attachment loss needed to expose the furcation entrance.

ii. The furcation location, shape and entrance diameter are also important with respect to accessibility to periodontal hygiene procedures.

b. Thickness of the investing alveolar process

Thick bone may predispose to the formation of deep horizontal and vertical osseous defects without soft tissue recession and resultant tortuous deep pockets.

Dr. Murray Arlin has a private practice in periodontics in Weston, Ont.

We are pleased to present the first publication of this original article written specially for Oral Health.

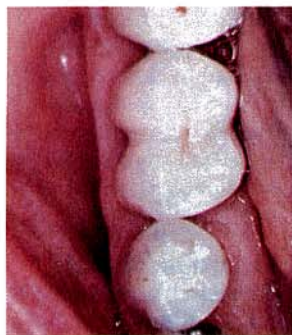

Fig. 1 — With early furcation involvement, the prosthetic preparation and restoration are "barrelled" in order to eliminate the roof of the furcation. The accentuated buccal and/or lingual grooves greatly facilitate oral physiotherapy in the furcation area.

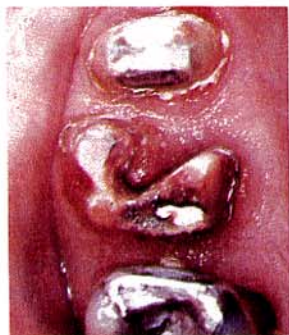

Fig. 2 — Occlusal view of the preparation that has eliminated an advanced Class II mesial furcation involvement. The same "barrelling" principle applies here as in the tooth treated in Figure 1. The extent of the "barrelling" must be limited by the accessibility of the "cul de sac" area to adequate oral physiotherapy.

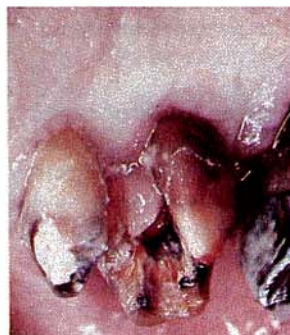

Fig. 3 — Palatal view of the same first molar (as seen in Figure 2) 8 weeks following the initial tooth preparation. In spite of the patient's best efforts, the palatal view shows hyperplastic tissue indicating that this extent of "barrelling" presents a situation that cannot be maintained.

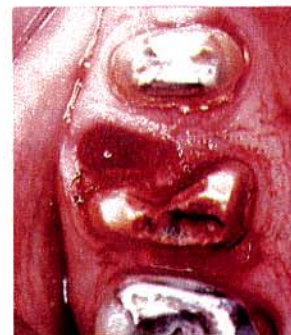

Fig. 4 — Definitive treatment with more extensive furcation invasion as seen in Figures 2 and 3 necessitates breaking through the buccal isthmus and removal of the resected single root. With the improved access, periodontal health can be more predictably maintained.

Thin bone is often accompanied by gingival recession which may result in easier access to the furcation.

c. Enamel projection

As the enamel may project to a varying degree into the furcation area, the lack of a connective tissue attachment (which is impossible with enamel) may allow direct access for bacteria into this area.⁷

d. Enamel pearl

The enamel pearl is an isolated island of ectopic enamel and its location is significant when the pearl communicates with marginal periodontal breakdown.

e. Pulpal pathology

Progressing via lateral canals, pulpal disease may act as a factor in furcation involvement. The importance of diagnosis with "Combined Lesions" is critical in determining the correct treatment.

f. Iatrogenic factors

Overhanging, subgingival margins interfere with plaque removal and predispose to furcation involvement. The incomplete root resection may also act as a contributing factor in progressive periodontal deterioration and pain⁸ as the "furcation" has not totally been eliminated.

Diagnosis

Radiographs are helpful but are not inadequate when used alone to detect furcation involvement. The periodontal probe, the pigtail explorer and the Nabers probe are more useful in determining the extent of furcation invasion but they also have their limitations. Certain cases demand exploratory flap procedures and even then at times, the extent of the attachment loss only becomes apparent after root resection. Where this

possibility exists, it is prudent to advise the patient during the pre-surgical consultation, that a decision for extraction during the surgical procedure might become the treatment of choice.

Indications for extraction of teeth with advanced furcation involvement

- where periodontal bone loss is jeopardizing the adjacent tooth (teeth) and the furcation cannot be definitively treated.
- discomfort that is unlikely to be relieved by periodontal therapy.
- the furcated first molar is bordered by a sound, second molar and second pre-molar.

Contra-indications for tooth resection

- medically compromised
- cost beyond patient's budget
- inadequate residual periodontal support and/or excessive mobility
- poor root form and/or tooth position
- severe, residual negative periodontal architecture anticipated after the resection procedure
- root fusion or inadequate root separation
- non-strategic tooth in whole masticatory apparatus
- changing a trifurcation into a bifurcation
- alternative conservative or regenerative periodontal procedures which are predictable
- difficult post-surgical maintenance

Indications for tooth resection

- in general, for strategic teeth that cannot be predictably maintained in a conservative manner, and where resection provides the best long-term prognosis
- terminal molar with a sound antagonist

- strategic abutment tooth
- severe disease isolated to only one molar root
- severe disease in the furcation aspect but good periodontal root support around the remaining root structures
- root proximity causing periodontal problems
- untreatable caries, resorption, fracture or other endodontic complications on one root.

Classification of furcation management

Mandibular and maxillary molars

- Class I – non-surgical maintenance by root scaling and curettage
– gingivoplasty and/or odontoplasty (tooth reshaping – Fig. 1)
- Class II – same as Class I plus osteoplasty and/or osteoectomy

Mandibular molars

Class III –

- a. “Tunneling”, i.e., opening the furcation to allow: “through-and-through” cleansing where root anatomy allows and the patient is highly motivated (endodontics and prosthetics are not indicated) (Fig. 8).
- b. Root separation (bicuspidation) – where sufficient periodontal support remains on both roots.
- c. Hemisection – where at least one root is maintainable (Figs. 9 & 10)
- d. Root amputation (i.e. maintenance of the whole clinical crown) – where patients are capable of cleansing the area and the tooth is also prosthetically maintainable for a relatively long period (Fig. 11-13).

Maxillary Molars

Class III –

- a. Root amputation – where one root is untreatable, the remaining roots have adequate support and the crown does not require a prosthetic restoration (Fig. 7).
- b. Hemisection – where only the palatal or both buccal roots are maintainable.
- c. Trisection – where Class III furcations exist with

long and divergent roots. Periodontal and prosthetic considerations determine if certain resected segments need to be extracted (Fig. 2-4).

Endodontic considerations

Although there is a conflicting body of opinion, where endodontic therapy should be carried out *before* or *after* tooth resection, the author prefers the latter approach. Should an unpredicted extraction become the treatment of choice, endodontic treatment would not have been done unnecessarily. As well, it is the author's experience that the patient will have no significant adverse effects if endodontic therapy is instituted within two weeks following tooth resection. (Long-term vital root resection should be considered a high risk procedure.)

Prosthetic considerations

Definitive treatment of Class II and Class III furcations may involve prosthetic, endodontic, as well as periodontal disciplines. Sectioned molars present the restorative dentist with a challenging situation because usually the roots have minimal residual tooth structure (often with undercuts) as well as minimal retention (often requiring post and core fabrication). Crown preparations must be contoured not only to follow the unusual root shape, but also to create maximum accessibility to the gingival third (Fig. 6). A common mistake is the assumption that the final crown contour must closely mimic the contours of a “normally” shaped crown (Fig. 5).

Class I and early Class II furcations can usually be eliminated with judicious odontoplasty. For instance, the buccal and lingual grooves of a mandibular molar should be “barrelled”, i.e. an accentuated groove prepared running occluso-gingivally, the full length of the anatomic crown. With moderate to advanced Class II furcations, endodontic treatment and/or a full crown restoration may be necessary (Fig. 1).

Class III furcations that are “tunnelled open” (Fig. 8) rather than resected may require a full crown restoration. Where possible, the crown margins should not extend onto the root surface. When it is necessary to cover the root surface however, it is best to recreate the original root contour while modifying the crown portion (as described for “tunnelled” Class III furcations).

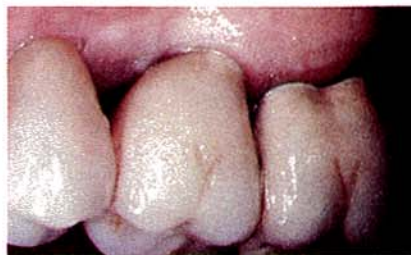

Fig. 5 – A mesio-buccal tri-section was carried out on the first molar. The crown anatomy incorporated into the final restoration demonstrates a common mistake in that there is insufficient access to the gingival third due to the overcontouring.

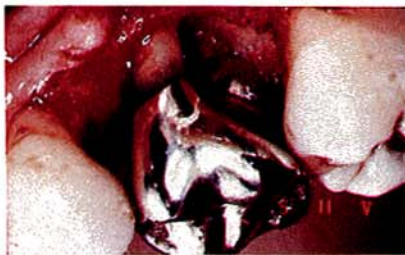

Fig. 6 – Although there is bone loss on the residual palatal and mesio-buccal roots, the anatomy of the full crown restoration allows improved access to the furcation area as compared to the crown in Figure 5.

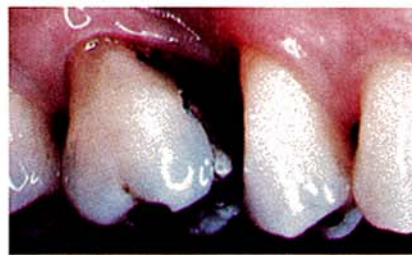

Fig. 7 – At times, a maxillary root amputation is carried out while the entire crown is left intact. Although this particular case is 5 years post-op with no apparent problems, a full crown restoration provides more protection against possible crown fracture.

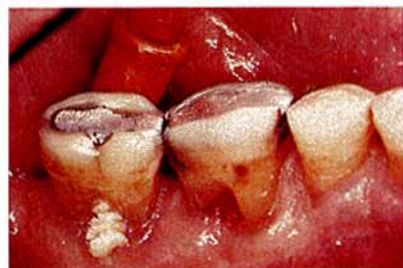

Fig. 8 — Where the roots of a mandibular molar diverge sufficiently, "tunnelling open" the furcation may at times be considered such that a proximal brush can pass through the furcation. Due to the tendency of developing root caries however, patients should first demonstrate an adequate level of oral hygiene.

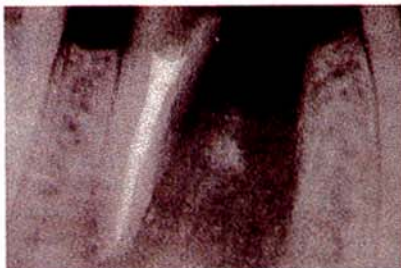


Fig. 9 — A periapical radiograph should be taken immediately after the tooth resection prior to suturing. This allows the dentist to modify the preparation, e.g. if the furcation has not been completely eradicated.

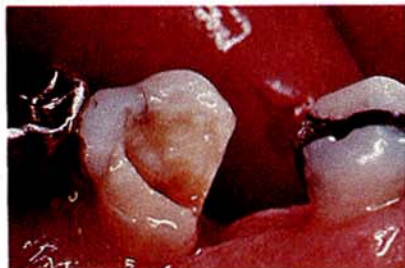

Fig. 10 — Lingual view 6 weeks following hemisection. The distal root of the mandibular first molar usually is more amenable to endodontic and restorative procedures as compared to the mesial root. The patient is now ready to have the area restored with a 3-unit fixed bridge.

When confronted with restoring two separated roots of a mandibular molar, it is very important to create sufficient interradicular space (perhaps by orthodontics) if the roots do not sufficiently diverge. When two individual crowns are fabricated, the interproximal area should be enlarged to allow the easy passage of a proxabrush. This can be accomplished by undercontouring the proximal aspects and locating the contact point (or solder joint) in a more coronal location.

If a decision to retain only one half of a hemisected mandibular first molar is to be made, then the distal root is the better half to retain (Figs. 9 & 10). With a mandibular second molar, however, it may be more advantageous to retain the mesial root in order to shorten the edentulous span.

When preparing the mandibular root, the concavity (especially on the mesial root of the mandibular first molar) and the minimal amount of tooth structure, present the dentist with the most delicate of prosthetic procedures. The final crown contour should incorporate a concave finish line at the marginal area which will subtly blend to a flat or convex contour as the crown extends in an occlusal direction.

When the root of a mandibular molar is amputated and the complete clinical crown is left intact, an intracoronal splint (e.g. wire and amalgam) may be

fabricated (Figs. 11-13). This is a medium-term restoration that may be indicated when the prognosis of the tooth is guarded.

With a maxillary molar, both halves are sometimes maintained (i.e. trisection) or one half may have to be removed (i.e. the two buccal roots or the palatal root). When both halves are maintained, it is important to incorporate a wide open mesio-distal embrasure as well as one normal continuous occlusal table. If only one of the maxillary molar segments is maintained a narrow occlusal table should be incorporated to direct occlusal forces axially. Great attention should be paid to creating undercontoured axial surfaces with a finish line that closely follows the root contour.

The principles of restoring a hemisected maxillary molar are similar to those as described with hemisected mandibular molars. The most common situation is when the mesio-buccal or disto-buccal root and overlying crown portion are removed (Figs. 3 & 4). Occasionally, a trifurcation is eliminated while all segments of the maxillary molar are maintained. This latter situation is similar to root separation (bicuspidization) of the mandibular molar. Orthodontic separation at times may be necessary as well as restoration via the use of individual telescopes in conjunction with an "overcasting".

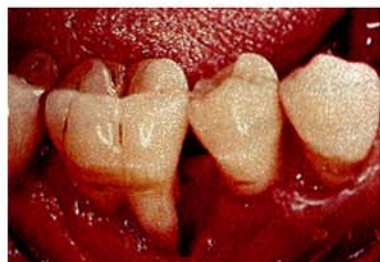

Fig. 11 — When hemisection in conjunction with a fixed bridge is not possible, an alternative approach may be root amputation (i.e. the clinical crown is left intact).

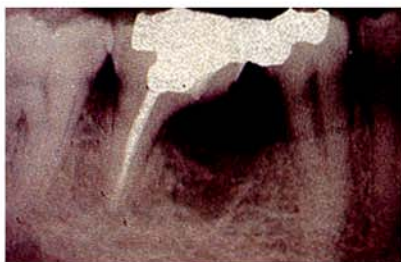

Fig. 12 — The periapical radiograph 4 months following the root amputation demonstrates significant osseous healing.

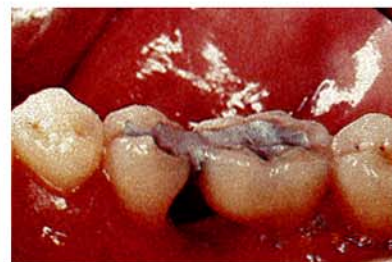

Fig. 13 — Fabrication of an intracoronal wire and amalgam splint will usually provide the patient with a "long term interim" restoration.


TABLE 1. Classification of Furcation Invasions

Horizontal Component*	Vertical Component** ***
Degree I Horizontal loss of periodontal tissue support is less than 3.0 mm.	A. Vertical destruction up to one-third of the total inter-radicular height (2-3 mm).
Degree II Horizontal loss of support exceeds 3.0 mm but does not encompass the total width of the furcation area.	B. Vertical destruction reaching two-thirds of the inter-radicular height (4-6 mm).
Degree III Horizontal "through-and-through" destruction of the periodontal tissue in the furcation.	C. Interradicular osseous destruction into or beyond the apical third (> 7 mm).

*Hampe, S.E., Nyman, S. and Lindhe, J.: Periodontal treatment of multi-rooted teeth: Results after 5 years. *J. Clin. Periodont.* 2: 126, 1975.

**Tarnow, D. and Fletcher, P.: Classification of the vertical component of furcation involvement. *J. Periodont.* 55: 283-284, 1984.

***Eskow, R.N. and Kapin, S.H.: Furcation invasions: Correlating a classification system with therapeutic considerations. Part I. Examination, diagnosis, and classification. *Compend. Cont. Educ. Dent.* 5: 487, 1984.

At times, a maxillary root amputation can be accomplished while leaving the entire anatomical crown intact (Fig. 7). This again is a somewhat similar situation to the root amputation as described with a mandibular molar. Ideally, a full crown does offer the advantages of minimizing the risk of tooth fracture as well as providing maximum control over the coronal anatomy and occlusion. 

Bibliography

1. Eskow, R.N., Dapin, S.H.: Furcation invasions: correlating a classification system with therapeutic considerations. Part II. Periodontal and restorative considerations in furcation management. *Compend. Cont. Educ. Dent.* 5: 527, 1984.
2. Saadoun, A.P.: Management of furcation involvement. *J. Western Soc. Periodont.* 33: 91, 1985.
3. Hirschfeld, L. and Wasserman, B.: A long term survey of tooth loss in 600 treated periodontal patients. *J. Periodont.* 49: 225, 1978.
4. Ross, I.F. and Thompson, R.H.: Furcation involvement in maxillary and mandibular molars. *J. Periodont.* 51: 450, 1980.
5. McFall, W.: Tooth loss in 100 treated patients with periodontal disease. A long term study. *J. Periodont.* 53: 539, 1982.
6. Langer, B., Stein, S. and Wagenberg, B.: An evaluation of root resection. A ten year study. *J. Periodont.* 52: 719, 1981.
7. Grewe, J.M. et al.: Cervical enamel projections: prevalence, location, and extent, with associated periodontal implications. *J. Periodont.* 36: 460, 1965.
8. Backman, K.: The incomplete root resection. Case presentations. *Int. J. Perio. Res.* 3: 61, 1972.