

# A CASE FOR CROWN LENGTHENING

Crown lengthening can be a necessary surgical procedure prior to restoring some badly damaged or decayed teeth

**O**n March 16, 1982, a 32-year-old woman arrived for treatment with the chief complaint that her fillings were frequently breaking and falling out, especially if she flossed. The examination revealed abundant plaque, multiple caries and restorations (many of them inadequate), but yet insignificant periodontal pocket depth or attachment loss. There were also endodontic complications.

With improved home care, the prognosis was excellent periodontally. The restorative prognosis however was dependant on endodontic therapy as well as the availability of access to adequate sound clinical tooth structure (in this case, most of the teeth exhibited very deep subgingival caries and/or pre-existing inadequate restorations).

Figures 1-6 (p. 26-27) show the buccal and palatal views of the patient's upper left quadrant before and after surgery. Similar procedures were carried out in all areas of her mouth. Describing details of the surgical technique is not within the scope of this article but the surgery necessitated removal of gingival and osseous tissue as well as apical

positioning of the gingival flaps.

Maintaining a healthy periodontium is a prerequisite to successful long-term restorative therapy. The restorative dentist should therefore understand the nature of the attachment apparatus (the biological response and physical dimensions), especially when placing subgingival restorations because of inadequate clinical crown length.

The physical dimensions of the dento-gingival junction have been previously described.<sup>1</sup> In one study, the sulcus was on average close to 1 mm in length while the junctional epithelium and supracrestal connective tissue attachment to the tooth were also about 1 mm in length. The junctional epithelium and supracrestal connective tissue attachments taken together have been described as the *biological width*. Clinically, this means that the restorative dentist must have a minimum of 3 mm (2 mm for the biological width and at least 1 mm for the sulcus) of sound tooth structure coronal to the level of the crestal

bone. Thus, when restorations, decay, resorption or subgingival fractures encroach closer than 3 mm to the osseous crest, the biological width has been violated.

Assuming the tooth is salvageable, a surgical crown lengthening procedure is necessary in order to properly carry out the restorative procedure. Several studies<sup>2,3,4,5,6</sup> have shown what happens if a restoration violates the biological width. These complications include gingival inflammation, bleeding and irreversible loss of attachment with infra-bony osseous defects and pocket formation. In contrast, when carrying out sur-

gical crown lengthening, the tissues are judiciously resected such that adequate clinical crown length is achieved. At the same time, infra-bony osseous defects and clinical pocket formation are avoided.

The concepts of surgical crown lengthening to gain access to sound tooth structure are applicable both to multiple areas (Figs 1-6) and to single teeth (Figs 7-9).

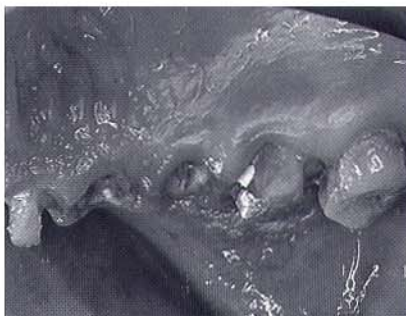Dr. Arlin is a periodontist with a practice in Weston, Ontario. He is also a lecturer with the University of Toronto Faculty of Dentistry



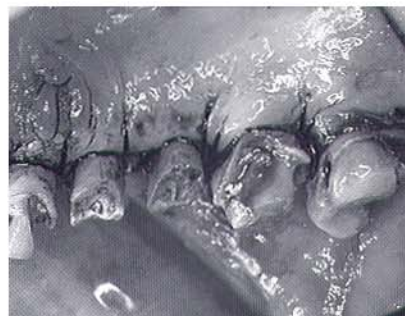BY MURRAY L. ARLIN, DDS

## REFERENCES

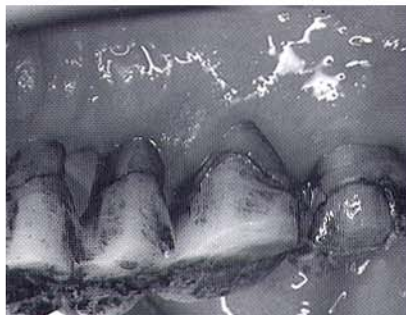
1. Gargiulo, A.W., Wentz, F.M. and Orban, B. "Dimensions of the dentogingival junction in humans." J PERIODONTAL, 32:261, 1961.
2. Ingber, J.S., Rose, L.F. and Coslet, J.G., "The biologic width-concepts in periodontics and restorative dentistry." ALPHA OMEGA, 70:62, 1977.
3. Maynard, J.G. Jr., Wilson, R.D., "Physiologic dimensions of the periodontium significant to the restorative dentist." J PERIODONTOL, 50:170, 1979.
4. Stern, N., Becker, A., "Forced eruption: biological and clinical considerations." J ORAL REHAB, 7:395, 1980.
5. Potashnick, S.R. and Rosenberg, E.S., "Forced eruption: principles in periodontics and restorative dentistry." J PROSTHET DENT, 48(2):141, 1982.
6. Parma-Benfanati, S., Fugazzotto, P.A., and Ruben, M.P., "The effect of restorative margins on the postsurgical development and nature of the periodontium, part 1." INT J PERIODONT REST DENT, 5(6):31, 1985. ♦



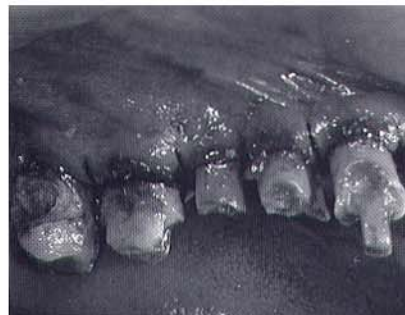1. Palatal view before surgical crown lengthening. Note that after removal of the caries and most of the old restorations there is adequate sound tooth structure to allow proper restorative treatment



2. Palatal view immediately after surgery. Compare to Figure 1 to see degree of apical tissue displacement that exposed adequate clinical crown length for future restorative treatment

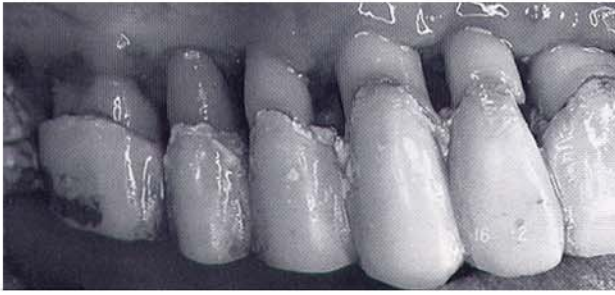


3. Palatal view six weeks after periodontal surgery. The temporary crown margins approximate the pre-existing gingival level

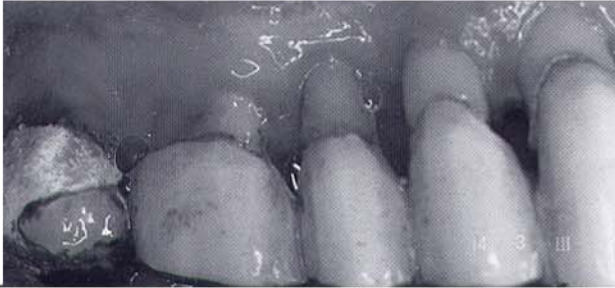


4. Buccal view immediately after surgery

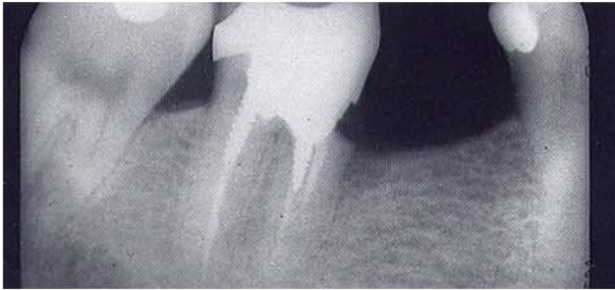



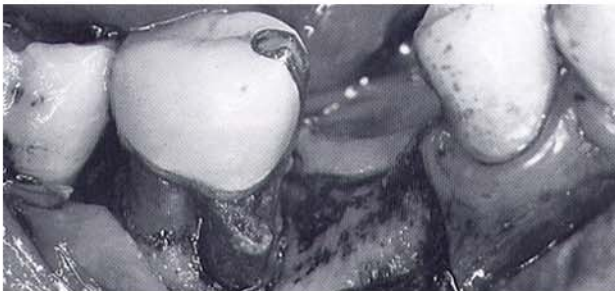5. Buccal view two weeks after surgery



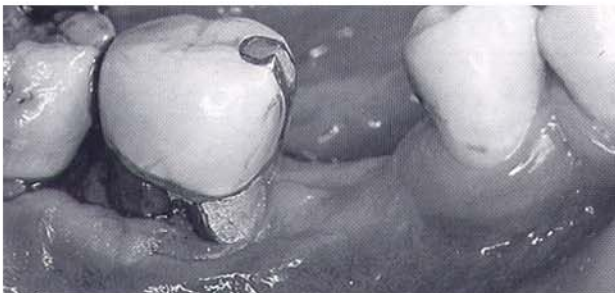6. Buccal view four weeks after surgery



7. Radiograph shows apparent "ditch" in the tooth



8. The subgingival defect and caries have been exposed. The osseous defect has also been eliminated with osteoplasty via "ramping"



9. View two months after surgery. The porcelain crown margin approximates the presurgical gingival level