

# Clinical Showcase

*Clinical Showcase is a series of pictorial essays that focus on the technical art of clinical dentistry. The section features step-by-step case demonstrations of clinical problems encountered in dental practice. This month's article is by Dr. Murray Arlin. If you would like to propose a case or recommend a clinician who could contribute to Clinical Showcase, contact editor-in-chief Dr. John O'Keefe at [jokeefe@cda-adc.ca](mailto:jokeefe@cda-adc.ca).*

## Mucogingival Surgery: Choosing the Right Technique

Dr. Murray Arlin, DDS, FRCD(C)

Some patients who suffer from gingival recession require intervention. Mucogingival therapy may be necessary to prevent further recession, correct cosmetic defects and eliminate root sensitivity. As with all aspects of dentistry, clinical decision making in this area is a science and an art. The practitioner must be aware of the different surgical techniques available for mucogingival problems, and which techniques are indicated in specific clinical situations.

Research has shown that some inflammation is always present with less than 2 mm of keratinized gingiva. Areas with minimal attached gingiva may also demonstrate extensive inflammation and ongoing recession when associated with subgingival restorations and poor plaque control.

The most common surgical techniques for the treatment of mucogingival problems are: the palatal autograft (free gingival graft), the coronally positioned flap (with or without a connective tissue graft) and the subepithelial con-

nective tissue autograft. There are 2 main types of palatal autografts: submarginal grafts, where the objective is to augment the gingiva to prevent further recession (but is not necessarily intended to cover the root surface), and root coverage, where the objective is to augment the tissue and simultaneously cover the root surface.

The palatal autograft, the coronally positioned flap and the subepithelial connective tissue autograft are the mucogingival procedures most frequently performed in my practice. This article provides a brief overview of these 3 techniques and proposes an algorithm to help practitioners decide which technique is best indicated in various clinical situations (Fig. 1). When determining which specific surgical approach is best, the clinician must assess the rate and extent of recession, residual tissue quality, functional demands (frenum pull, orthodontic treatment, prosthodontic treatment), esthetics and root sensitivity.

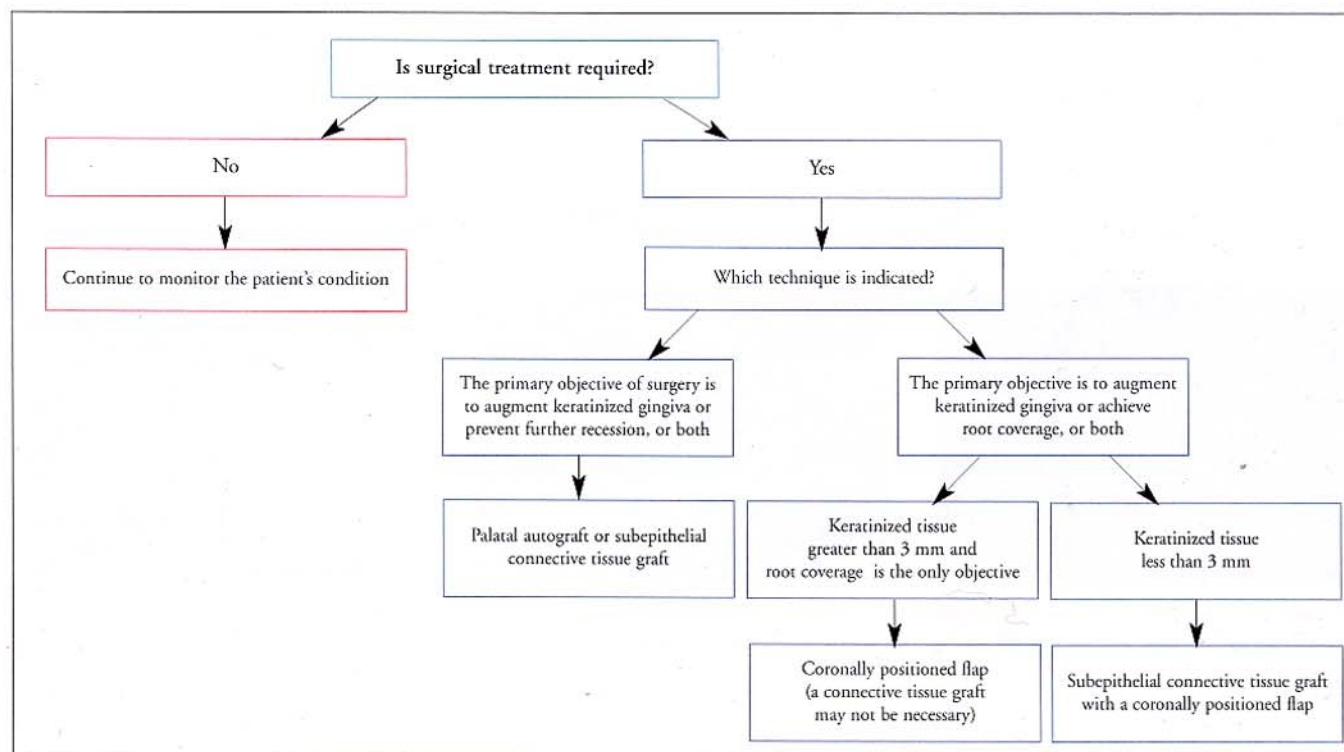
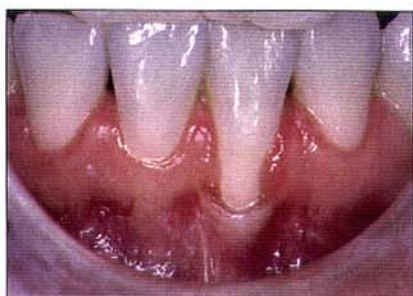
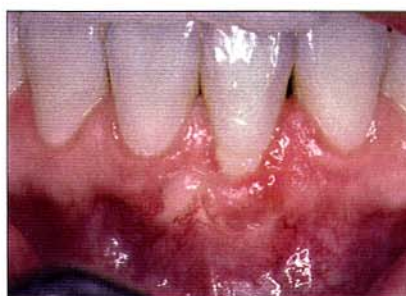
Figure 1: Proposed algorithm for the surgical treatment of mucogingival problems

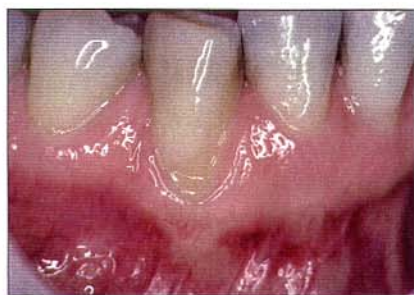## Subepithelial Connective Tissue Autograft ("Pita Pocket" Technique)



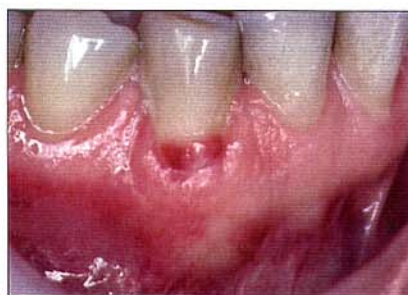**Figure 6a:** Pretreatment view showing significant recession and minimal keratinized tissue on tooth 43. A pouch-like recipient site, without releasing incisions, will be prepared.



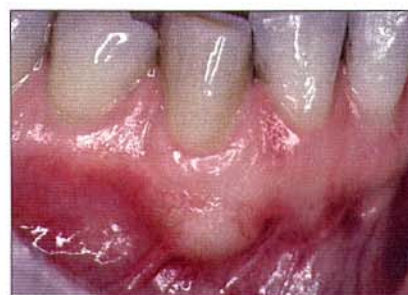**Figure 6b:** Four-month postoperative view shows 75% root coverage, which was limited because of the severity of the pretreatment defect involving loss of interproximal attachment.



**Figure 7a:** Preoperative view showing severe recession, total lack of keratinized gingiva and some interproximal attachment loss on tooth 31.

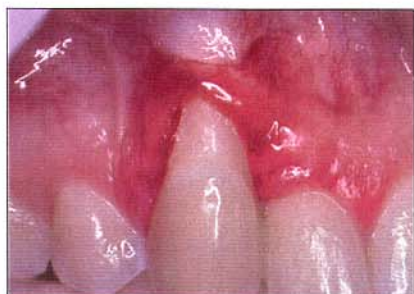


**Figure 7b:** Photograph taken 2 weeks after surgery. The connective tissue graft extends several millimeters subgingivally, even though a flap has not been raised.

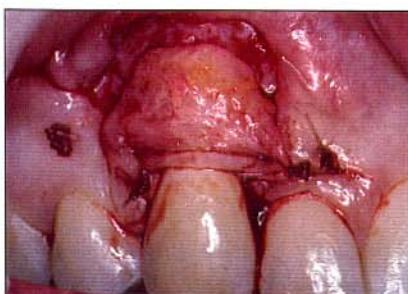


**Figure 7c:** Six-month postoperative photograph revealing excellent root coverage and augmentation of the keratinized gingiva.

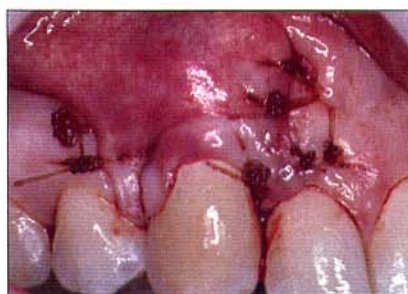
## Subepithelial Connective Tissue Autograft (Coronally Positioned Flap Technique)



**Figure 8a:** This 17-year-old patient was referred after an unsuccessful treatment by her dentist, who attempted a coronally positioned flap without a graft, despite the total lack of pretreatment keratinized gingiva. Note the severe recession, including loss of some interproximal attachment.



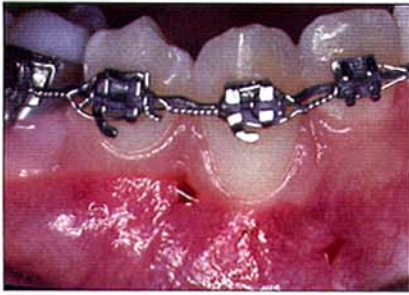**Figure 8b:** The connective tissue graft was secured to the recipient connective tissue bed with sutures.



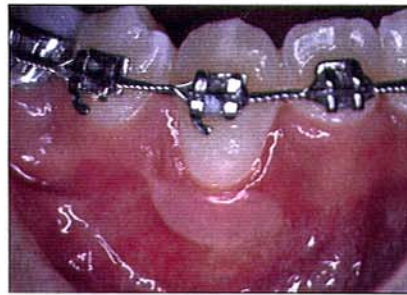**Figure 8c:** The mucosal flap has been coronally positioned over the connective tissue graft and sutured securely and without tension.



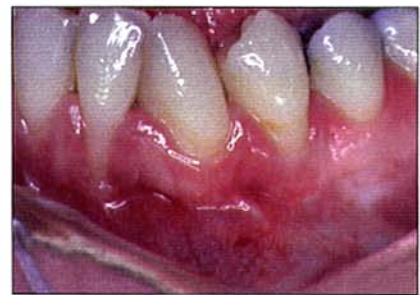### Palatal Autograft (Free Gingival Graft)



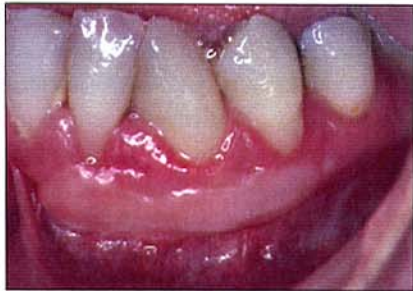**Figure 2a:** Pretreatment view showing total lack of keratinized gingiva on tooth 43.



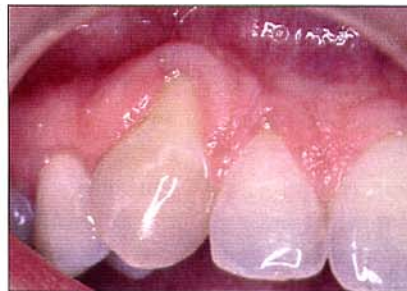**Figure 2b:** Post-treatment view showing augmentation of the gingiva after healing of the submarginal palatal autograft. Root coverage was not necessary in this case.



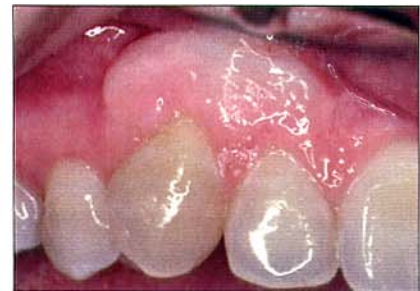**Figure 3a:** Pretreatment view showing minimal amount of keratinized gingiva on teeth 32, 33 and 34, as well as significant recession defect on tooth 32.



**Figure 3b:** Post-treatment view showing significant augmentation of the keratinized gingiva and partial root coverage on tooth 32.

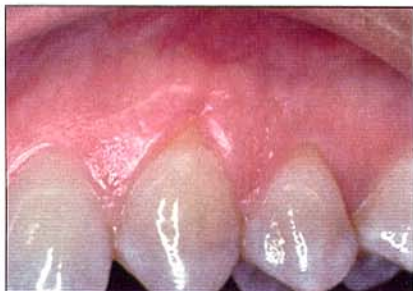

**Figure 4a:** Pretreatment view showing severe recession and total lack of attached keratinized gingiva on tooth 13.

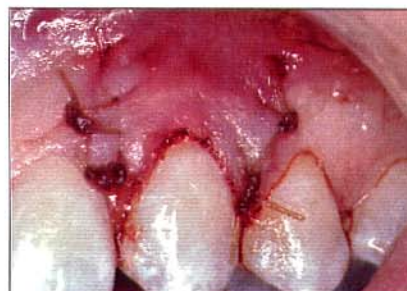

**Figure 4b:** Post-treatment view showing augmented keratinized gingiva and 75% root coverage. This case demonstrates the relatively poor esthetic result achieved with this particular technique (tire patch look).

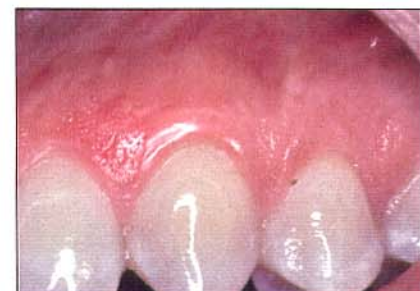### Coronally Positioned Flap (Without a Graft)



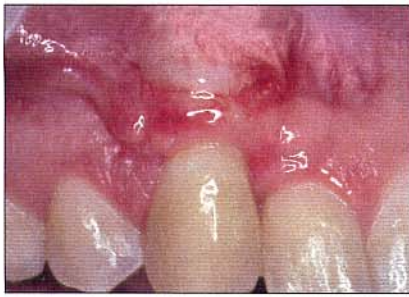
**Figure 5a:** This patient complained of root sensitivity and a cosmetic defect on tooth 23. Despite the recession, at least 3 mm of keratinized tissue was still present.



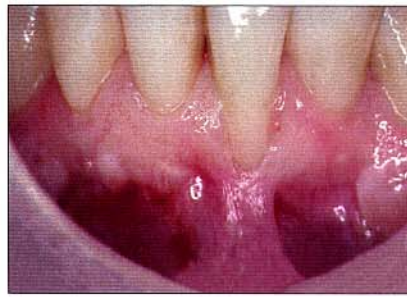**Figure 5b:** Root coverage was achieved with bilateral vertical releasing incisions and a coronally positioned flap. In this case, a connective graft was not required.



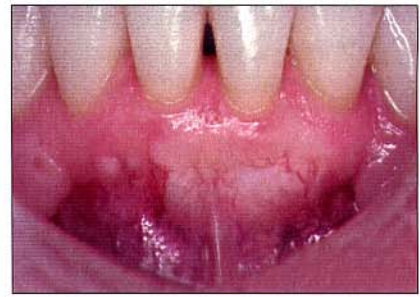**Figure 5c:** Photograph taken 6 months after surgery. The patient was very satisfied with the correction of the cosmetic defect and no longer complained of root sensitivity.



**Figure 8d:** Postoperative view showing 85% root coverage. Complete coverage could not be expected due to the severity of the pretreatment interproximal attachment loss.



**Figure 9a:** Pretreatment view showing severe recession and total lack of keratinized gingiva on tooth 31. Note the intact interproximal papilla and attachment.



**Figure 9b:** Post-treatment photograph taken 2 years after treatment shows complete root coverage and healthy gingiva. Complete root coverage can be predictable if the interproximal attachment and papilla are intact.

General practitioners should be aware of the different techniques available for treating mucogingival problems, and which techniques are indicated in specific clinical situations. However, mastering these surgical techniques requires appropriate training and experience. Patients who may need mucogingival surgery should be considered for referral to a periodontist for assessment and treatment. ♦



*Dr. Murray Arlin maintains a private practice limited to periodontics and implant dentistry in West Toronto, Ontario.*

*Correspondence to: Dr. Murray Arlin, 1436 Royal York Road, Suite 209, Weston, ON M9P 3A9. E-mail: [murray.arlin@utoronto.ca](mailto:murray.arlin@utoronto.ca).*

*The author has no declared financial interests.*