

When to Take a CBCT Scan for Implant Placement

Mark Nicolucci, DDS, MS, FRCD(C)

Implant dentistry has a particular need to assess the three-dimensional structure of the jaw bones. Traditionally two-dimensional radiographs have sufficed for most dentists' needs such as with restorative or endodontics. While the advent of cone-beam computerized tomography (CBCT) has improved our diagnostic capability in many cases, (e.g. complex endodontic canals, furcation involvements, canine exposure, wisdom tooth removal, etc.), two-dimensional radiographs still dominate as the radiograph of choice for most dentistry.

Implant dentistry is where this standard shifts. The nature of nearly all surgical implant placement involves three-dimensional placement into a non-visible space. Two-dimensional radiographs can provide important information but they often lack the oral-facial dimension that completes the picture.

This idea provokes a question, "When is it appropriate to take a CBCT scan for implant placement?"

In the year 2000, the American Academy of Oral and Maxillofacial Radiology (AAOMR) produced selection criteria for radiographs used in the placement of dental implants.¹ Here they made a recommendation that, "some form of cross-sectional imaging be used for implant cases and that conventional cross-sectional tomography be the method of choice for gaining this information for most patients receiving implants." This referred only to most patients, thus not necessarily all. But this position paper was followed up by a more recent position statement in 2012.² In this new paper's summary, they recommend, "that cross-sectional imaging be used for the assessment of **all** dental implant sites and that CBCT is the imaging method of choice" (author's emphasis). This created some concern. Theoretically, any dentist who read the summary may think that if they didn't have a cross-sectional image (e.g. CBCT scan) and had placed an implant they were performing below a standard of care recommended by the AAOMR. In the actual bulk of the paper they had tempered this idea, stating, "The decision to perform a CBCT examination must be clinically justified and based on professional judgment (that is, the judgment of the clinician is that the use of CBCT will

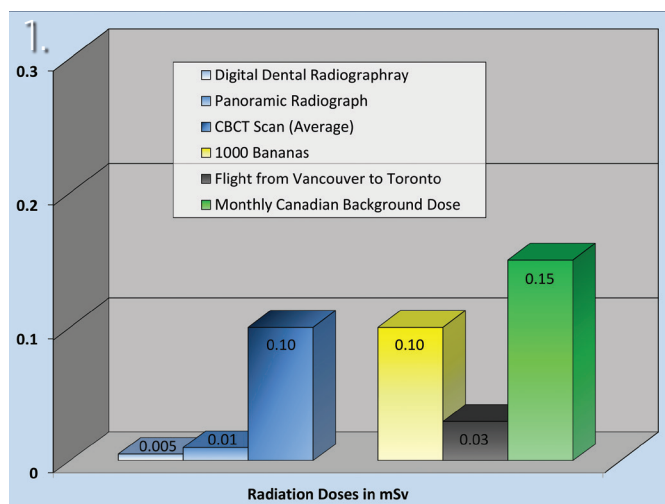
potentially provide information needed for prosthetic treatment planning, implant selection, and/or surgical placement)." So, in the end, it was the clinician's judgement of whether or not CBCT would provide "needed" information for treatment.

The question "When is it appropriate to take a CBCT scan for implant placement?" remained mostly unanswered. The author has encountered many different philosophies from colleagues, ranging from the opinion that CBCT is rarely needed to the idea that CBCT is essential for every implant case. This article attempts to provide groundwork for the decision-making process to answer this question.

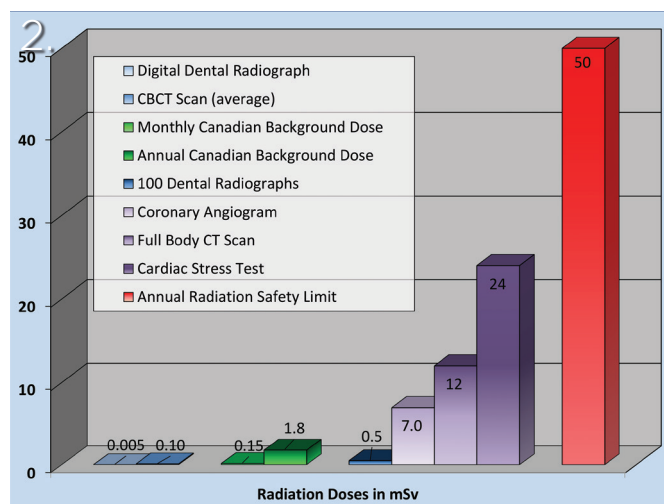
Deciding to use CBCT technology requires a risk versus benefit assessment. The colleges throughout Canada often make this clear by publishing standards of practice that demand a risk versus benefit assessment that is patient specific. To properly make this assessment, the risks need to be defined.

ALARA is an acronym for a concept that is pervasive throughout radiology. It stands for "As Low As Reasonably Achievable" and is a principle for the use of radiation in humans and animals. The idea stems from the concept that any radiation is potentially harmful so, when using radiation, the exposure should be minimized. Because CBCT produces more radiation than standard dental radiographs (**Fig. 1**), there would have to be a benefit of acquiring a CBCT scan over a standard dental radiograph to justify the use of CBCT, according to ALARA. This is important to recognize as often clinicians will cite the benefits of CBCT in comparison to no radiographic examination when the appropriate comparison should be to other radiographs of lower radiation exposure. Some have further enhanced this concept, proposing ALADAIP (As Low as Diagnostically Acceptable being Indication-oriented and Patient-specific).³ They suggest we should follow ALARA and the use of radiology needs to be prompted by an indication that is specific for the patient being treated.

CBCT scans are produced quickly much the same as a panoramic image. Any inconvenience to the patient is really no different than a panoramic image except that CBCT machines are not as common



Radiation doses of less than 1 mSv.



Radiation doses from 0-50 mSv.

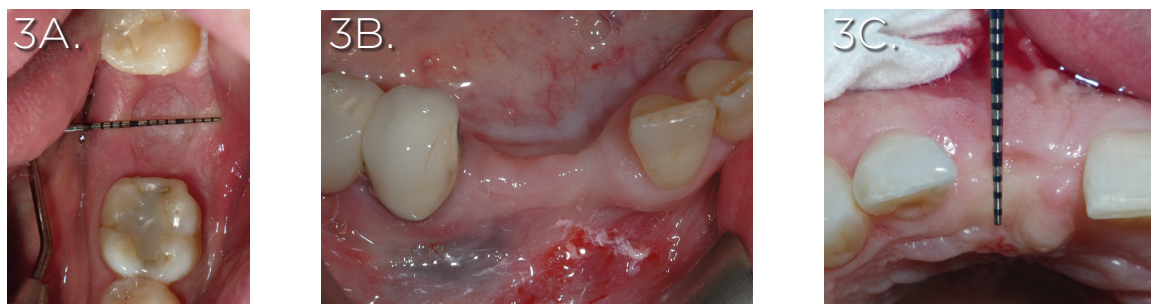and if one is not readily available the patient may have to drive to a location where one is present. The main negatives of CBCT compared to conventional dental radiography are an increased financial cost and an increased radiation dose. The cost of CBCT scans vary as the cost of the machines that produce these scans also vary widely. From the author's experience, the price of a CBCT scan are often in the range of \$100 to \$500 depending on where it is being taken, with what machine, and what setting are used.

The radiation exposure from a CBCT is often measured in mSv (millisievert). The radiation dose of the exposure can vary widely depending on the manufacturer, the machine settings, and the field of view. These values can range from 0.01 to 1 mSv¹⁰ with an approximate average dose of 0.1 mSv. This can be contrasted to the radiation dose from a panoramic radiograph which can also vary greatly, but has an approximate average dose of 0.01 mSv, or 1/10th the dose of a CBCT scan (Fig. 1). To further complicate this comparison, the technologies producing either type of radiograph are constantly improving allowing us better imaging and a reduced radiation dose. Although the application of radiation, no matter how small, may increase a patient's risk of cancer, the amounts used in CBCT scanning are minor compared to many other events (Fig. 2). In conclusion, the financial costs and radiographic risks of using CBCT are minor.

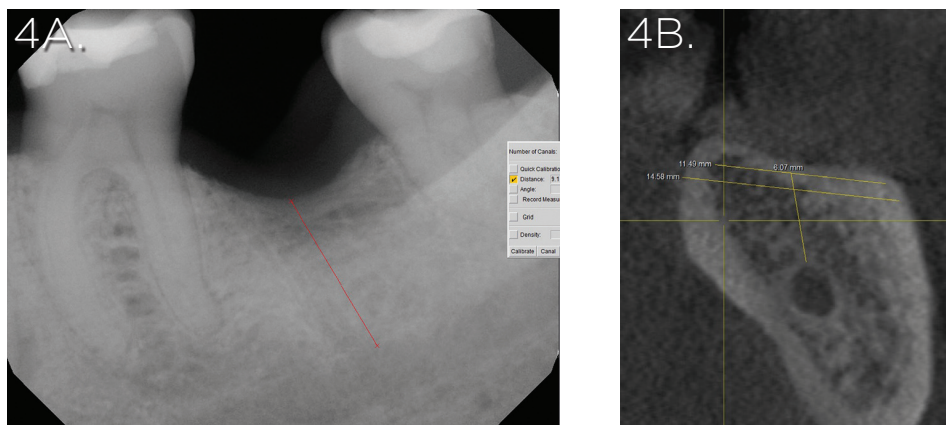
To justify CBCT use the benefits need to outweigh the risks. As these risks are minor, if producing a CBCT scan provides a benefit for your patient, it would likely outweigh the risks and be prudent to develop. These benefits can be an improved treatment course or a reduction in the risk of treatment complications. Complications in implant dentistry are unfortunately common and can range from minor to severe. One of the most common complications in implant dentistry is implant malposition. This can result in a host of complications: fenestrations, dehiscences

and recession, difficult restoration, poor biomechanics, loss of interproximal structure, damage to adjacent anatomy, and many others. One of the most severe complications is damage to the inferior alveolar nerve. A meta-analysis⁴ recently reported an incidence of temporary damage to this nerve in 13% of mandibular implant placement treatments and 3% of the time the damage was permanent. While these numbers are not common, the fact that the numbers are above 1% for a situation that may be completely preventable is alarming.

The risk of a complication and the ability of a CBCT scan to mitigate that risk is situation specific. Perhaps the most obvious indication for a CBCT scan is a questionable amount of bone in the oral-facial dimension. Ideally an implant site has at least 7 mm of bone in this dimension: 2 mm for the facial plate, 4 mm for the implant, and 1 mm for the palatal or lingual plate. Some cases will obviously exceed these amounts, others will obviously not, and some will be questionable (Fig. 3). Other factors of osseous anatomy that may only be revealed by a CBCT scan are angulations of the alveolar bone, presence of undercuts, position of the maxillary sinus or nasal floor, and position of neurovasculature. While CBCT can adequately capture these areas in three dimensions, the decision-making process asks us to compare this benefit to what could be gained from radiographic exams with less risks. A recent study¹¹ compared the measurement of vertical bone height in the posterior mandible with either a panoramic radiograph or a CBCT scan. They compared the measurements from the alveolar crest to the roof of the inferior alveolar canal and found that the measurements were very similar and varied by less than 1 mm. A caveat to such information; their panoramic images were well calibrated and captured. Moreover, the same is not true for periapical images (Fig. 4) where there can be significantly more inaccuracy.



A) Edentulous 3.7 site measuring approximately 14 mm wide and providing ample width for implant placement. B) Edentulous 4.4 and 4.3 sites with an evident narrow ridge and likely insufficient bone for implant placement. C) Edentulous 1.1 site with an unknown amount of bone in the oral-facial dimension.

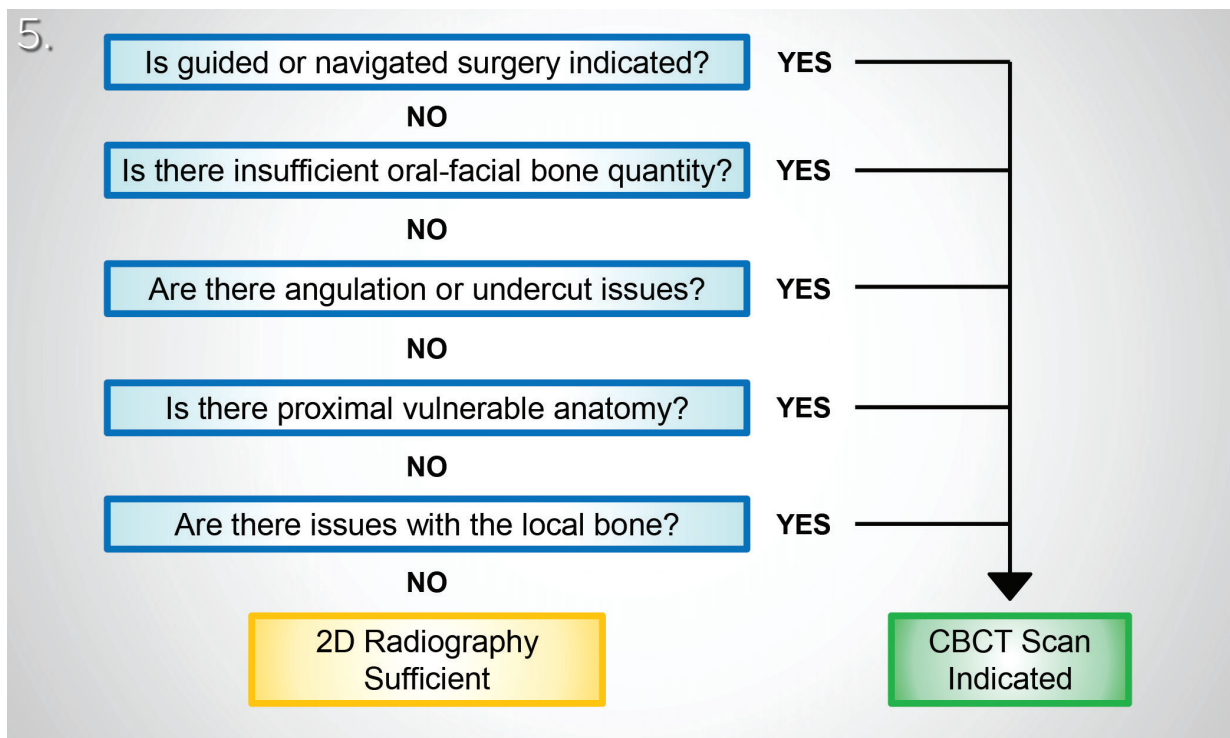


A) Periapical radiograph of the edentulous 3.7 area that digitally measures 9 mm of height from the mandibular canal to the alveolar crest. B) Cross-sectional image of the 3.7 area from a CBCT scan reveals the height is in fact 6 mm. The periapical radiograph was measuring from the mandibular canal to the lingual height of the alveolar crest, not to center of the alveolar crest which is the likely osteotomy site. In this case, implant placement based only on the periapical radiograph has a high likelihood of inferior alveolar nerve damage.

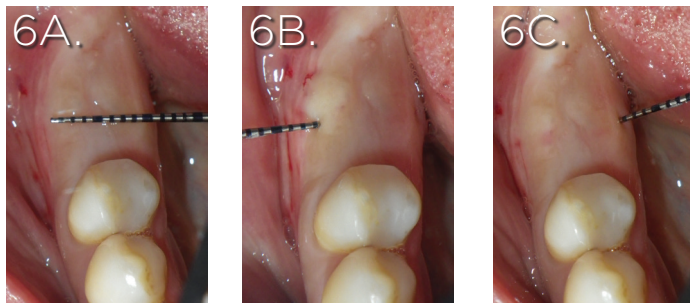
CBCT can also change how implant cases are treated. Digital dentistry is growing fast and CBCT technology is linked to its progress. The ability to take three-dimensional radiographs faster, quicker, at lower cost, and with reduced radiation has opened the opportunity for more treatment possibilities. CBCT data can be fused with intra-oral scanners or fiducials allowing surgically guided and/or navigated surgery. Studies have shown these techniques have inherent inaccuracy, especially in edentulous cases⁷ but they tend to improve accuracy compared to free-hand surgery.⁸ These techniques are in their infancy and future improvements are expected which may further improve their reliability. However, a recent well-controlled clinical trial⁶ showed equivalent failure and complication rates with either free-handed or guided implant placement suggesting that the improved accuracy provided by guided surgery may not be meaningful to the outcome.

A recent study by Choi et al.⁸ looked at the factors that may make freehand placement inaccurate. They found four factors were significantly associated with a decreased accuracy of implant placement: placing multiple adjacent implants, placing implants in sites with no adjacent teeth, placing implants after extraction sites had healed, and having limited clinical experience. If an implant treatment would involve some or all of these factors, a clinician could expect accurate implant placement to be more difficult to achieve. But a modest lack of accuracy is not always critical to the treatment. For a patient with a high smile line, accurate placement in the anterior maxilla can be crucial. Alternatively, when placing an implant into a second molar site with great bone quantity and no nearby anatomy, accuracy would not be as important.

Another consideration is how the treatment is planned. Some digital treatment pathways allow the fabrication of immediate prostheses based upon planned implant positions. Such treatment



Flowchart demonstrating a decision pathway for deciding whether CBCT is indicated for implant placement.



Edentulous 4.6 site with approximately 9 mm of ridge width. Bone sounding on both the facial and lingual reveals thin overlying gingiva approximately 1 mm deep. This data gives an estimation of 7 mm of underlying bone in an oral-facial dimension which would be sufficient for implant placement.

necessitates the use of CBCT to plan the implant placement and fabricate implant guides. If this treatment is desired, CBCTs must obviously be produced as they are integral to the treatment process.

Figure 5 is a flowchart of five questions to help determine whether CBCT is indicated for an implant placement case. If any step yields a positive response a CBCT would be indicated otherwise one would move to the next step.

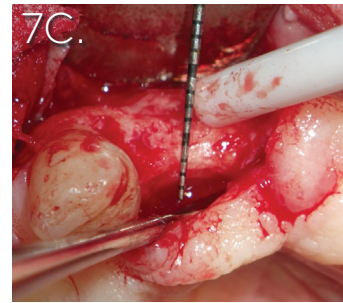
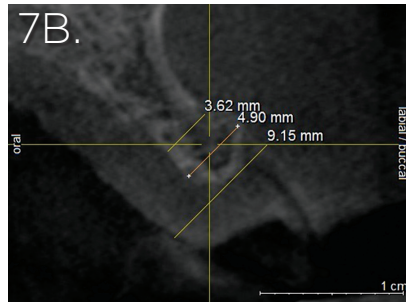
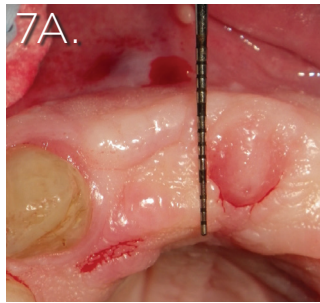
The first step is to determine whether guided or navigated surgery is indicated. This needs to be a subjective assessment

based upon the clinician's skill, the challenges of the treatment, the treatment plan itself, and the patient's desires.

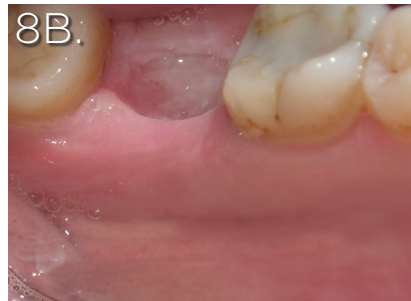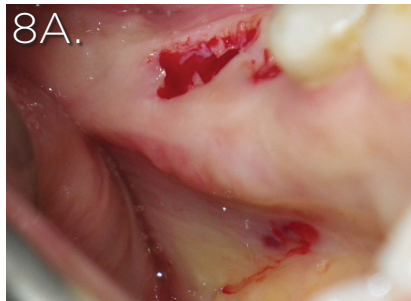
The second step is to determine whether sufficient bone quantity exists oral-facially. Bone sounding can help determine this (**Fig. 6**) but if there is doubt a three-dimensional radiograph should be developed to reveal this aspect of the implant site. One should be especially careful not to clinically over-estimate the amount of bone present due to thick palatal tissues (**Fig. 7**).

➔ on page 14

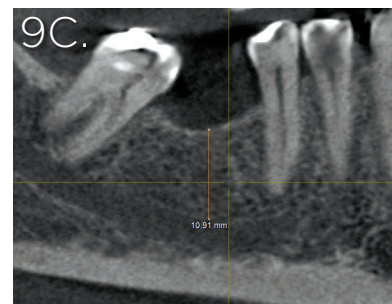
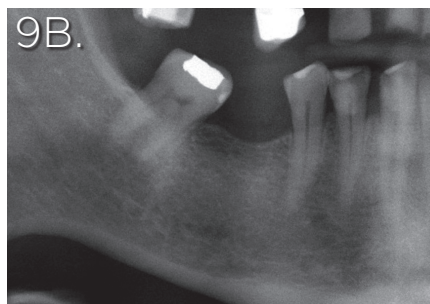
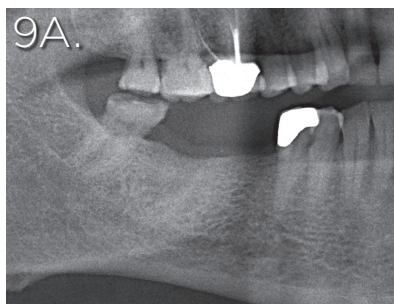
→ from page 11



A) Edentulous 1.2 to 2.2 area which clinically looks to be over 10 mm wide. Experienced clinicians will recognize that the incisive papilla typically sits on the palatal side of the alveolar ridge not in the center as depicted. This is suggestive of thick palatal tissues hiding narrow alveolar bone. B) A CBCT scan confirms the suspicion of a narrow ridge. C) Reflection of the tissues over 1.2 reveals an alveolar crest only 3-4 mm wide. The thick palatal tissues were comprising most of the clinical width of the ridge.



A) An evident undercut of the left mandible. Even though the ridge is wide the undercut should be evaluated in three dimensions to ensure sufficient bone volume for implant placement is also present apically. B) No mandibular undercut appears evident at the edentulous 3.7 site. This area should still be palpated to see if the tissues are potentially hiding an undercut. Palpation and visual inspection need to produce clear unequivocal results that an undercut is not significantly present if only relying on two-dimensional radiography.



A) Panoramic radiograph with a clearly defined mandibular canal below edentulous sites 4.7 and 4.6. This radiograph would be sufficient to judge the distance of the alveolar crest to the mandibular canal within a 1 mm tolerance. B) Panoramic radiograph with a poorly defined mandibular canal below the edentulous 4.6 site. Although one may assume where the canal lies, unless it is clear additional radiography is indicated. C) Transverse section of a CBCT scan of the same 4.6 site clearly depicting the canal and the distance to the alveolar crest.

The third step is an assessment of whether angulation or undercuts might be an issue. In the mandibular posterior, the submandibular fossa often presents within 10 mm of the alveolar crest and this can be assessed clinically (Fig. 8). If the mandible clearly extends well

apically before the fossa presents itself a CBCT scan may not be indicated. But if the presence or absence is unclear or the fossa presents close to where the anticipated apex of the implant might

→ on page 17

➔ from page 14

be, a CBCT scan should be produced. The mandibular anterior can often present with a lingual undercut and the anterior maxilla and mandible often have angulated alveolar bone. In addition to these common sites, one should be aware that all sites have the potential to have a significant angulation or undercut, potentially due to an angulated alveolar bone, bone resorption due to infection or extraction, or bone growth such as with exostoses and tori.

The fourth step is to determine whether or not there is nearby vulnerable anatomy. This includes the incisive canal, the mandibular canal, the mental canal, anterior loops of the mental foramina, the maxillary sinus, adjacent roots, the nasal floor, impacted teeth, and many other rarer items. The indication for a CBCT scan will vary with each item as some are more difficult to perceive on conventional radiographs and some are more sensitive to proximity (**Fig. 9**). A risk assessment of the potential to impact these structures should be taken and the prudent practitioner should use a CBCT scan if it can help clarify and significantly reduce such risk. This is especially important when dealing with the mandibular canal as damage to it can cause severe sequelae and it is unfortunately often an implant complication.⁴ Additionally, its anatomy can be complicated (e.g. anterior loop of the mental foramen) and it can be sensitive to proximity with many papers suggesting implants be placed at a minimum distance from the canal to avoid paresthesia.¹⁴

The fifth step is to determine if there are potential abnormalities in the area. For example, a CBCT scan can be used to help ascertain the quality of especially low bone density, to identify or localize the extent of pathology, or to determine whether a bone graft has integrated and how mature it might be. This last step can include many additional items as clinical situations inevitably produce scenarios that were unaccounted for.

If none of the above produces an indication for a CBCT scan, traditional two-dimensional radiographs should be sufficient for implant placement.

The International Congress of Oral Implantologists produced a consensus statement in 2012 that nicely summarizes this article.⁵ They stated:

“All CBCT examinations, as all other radiographic examinations, must be justified on an individualized needs basis. The benefits to the patient for each CBCT scan must outweigh the potential risks. CBCT scans should not be taken without initially obtaining thorough medical and dental histories and performing a comprehensive clinical examination. CBCT should be considered as an imaging alternative in cases where the projected implant receptor or bone augmentation site(s) are suspect, and conventional radiography may not be able to assess the true regional three-dimensional anatomical presentation. The smallest possible field of view should be used, and the entire image volume should be interpreted.”

As well, in 2009 the European Academy of Dental and Maxillofacial Radiology (EADMFR) but together a 20-point list on the use of CBCT that still holds true today (**Appendix 1**).

Appendix 1

EADMFR Basic Principles on the Use of Cone Beam CT

1	CBCT examinations must not be carried out unless a history and clinical examination have been performed
2	CBCT examinations must be justified for each patient to demonstrate that the benefits outweigh the risks
3	CBCT examinations should potentially add new information to aid the patient's management
4	CBCT should not be repeated 'routinely' on a patient without a new risk/benefit assessment having been performed
5	When accepting referrals from other dentists for CBCT examinations, the referring dentist must supply sufficient clinical information (results of a history and examination) to allow the CBCT Practitioner to perform the Justification process
6	CBCT should only be used when the question for which imaging is required cannot be answered adequately by lower dose conventional (traditional) radiography
7	CBCT images must undergo a thorough clinical evaluation ('radiological report') of the entire image data set
8	Where it is likely that evaluation of soft tissues will be required as part of the patient's radiological assessment, the appropriate imaging should be conventional medical CT or MR, rather than CBCT
9	CBCT equipment should offer a choice of volume sizes and examinations must use the smallest that is compatible with the clinical situation if this provides less radiation dose to the patient
10	Where CBCT equipment offers a choice of resolution, the resolution compatible with adequate diagnosis and the lowest achievable dose should be used
11	A quality assurance program must be established and implemented for each CBCT facility, including equipment, techniques and quality control procedures
12	Aids to accurate positioning (light beam markers) must always be used

13	All new installations of CBCT equipment should undergo a critical examination and detailed acceptance tests before use to ensure that radiation protection for staff, members of the public and patient are optimal
14	CBCT equipment should undergo regular routine tests to ensure that radiation protection, for both practice/facility users and patients, has not significantly deteriorated
15	For staff protection from CBCT equipment, the guidelines detailed in Section 6 of the European Commission document 'Radiation Protection 136. European Guidelines on Radiation Protection in Dental Radiology' should be followed
16	All those involved with CBCT must have received adequate theoretical and practical training for the purpose of radiological practices and relevant competence in radiation protection
17	Continuing education and training after qualification are required, particularly when new CBCT equipment or techniques are adopted
18	Dentists responsible for CBCT facilities who have not previously received 'adequate theoretical and practical training' should undergo a period of additional theoretical and practical training that has been validated by an academic institution (University or equivalent). Where national specialist qualifications in DMFR exist, the design and delivery of CBCT training programmes should involve a DMF Radiologist
19	For dento-alveolar CBCT images of the teeth, their supporting structures, the mandible and the maxilla up to the floor of the nose, clinical evaluation ('radiological report') should be made by a specially trained DMF Radiologist or, where this is impracticable, an adequately trained general dental practitioner
20	For nondento-alveolar small fields of view (e.g. temporal bone) and all craniofacial CBCT images (fields of view extending beyond the teeth, their supporting structures, the mandible, including the TMJ, and the maxilla up to the floor of the nose), clinical evaluation ('radiological report') should be made by a specially trained DMF Radiologist or by a Clinical Radiologist (Medical Radiologist) OH

Oral Health welcomes this original article.

References

1. Tyndall DA, Brooks SL. Selection criteria for dental implant site imaging: a position paper of the American Academy of Oral and Maxillofacial Radiology. *Oral Surg Oral Med Oral Pathol Oral Radiol Endod* 2000;89:630-7.
2. Tyndall DA, Price JB, Tetradis S, Ganz SD, Hildebolt C, Scarfe WC. Position statement of the American Academy of Oral and Maxillofacial Radiology on selection criteria for the use of radiology in dental implantology with emphasis on cone beam computed tomography *Oral Surg Oral Med Oral Pathol Oral Radiol* 2012;113: 817-826.
3. Oenning AC, Jacobs R, Pauwels R, Stratis A, Hedesiu M, Salmon B, Dimitra Research Group. Cone-beam CT in paediatric dentistry: DIMITRA project position statement. *Pediatr Radiol*. 2018;48(3):308-16.
4. Lin CS, Wu SY, Huang HY, Lai YL. Systematic Review and Meta-Analysis on Incidence of Altered Sensation of Mandibular Implant Surgery. *PLoS One*. 2016 Apr 21;11(4):e0154082. doi: 10.1371/journal.pone.0154082.
5. Benavides E, Rios HF, Ganz SD, An CH, Resnik R, Reardon GT, Feldman SJ, Mah JK, Hatcher D, Kim MJ, Sohn DS, Palti A, Perel ML, Judy KW, Misch CE, Wang HL. Use of cone beam computed tomography in implant dentistry: the International Congress of Oral Implantologists consensus report. *Implant Dent*. 2012 Apr;21(2):78-86. doi: 10.1097/ID.0b013e31824885b5.
6. Tallarico M, Esposito M, Xhanari E, Caneva M, Meloni SM. Computer-guided vs freehand placement of immediately loaded dental implants: 5-year post loading results of a randomised controlled trial. *Eur J Oral Implantol*. 2018;11(2):203-213.
7. Seo C, Juodzbalsys G. Accuracy of Guided Surgery via Stereolithographic Mucosa-Supported Surgical Guide in Implant Surgery for Edentulous Patient: a Systematic Review. *J Oral Maxillofac Res*. 2018 Mar 31;9(1):e1. doi: 10.5037/jomr.2018.9101.
8. Choi W, Nguyen B, Doan A, Girod S, Gaudilliere B, Gaudilliere D. Freehand versus guided surgery: factors influencing accuracy of dental implant placement. *Implant Dent* 2017;26:500-509
9. Katsoulis J, Katsoulis K. Accuracy of free hand vs pilot drill and fully guided oral implant placement. *Clin Oral Imp Res*. Oct 2017; 28 S14: 453-453.
10. Jacobs R, Quirynen M. Dental cone beam computed tomography: justification for use in planning oral implant placement. *Periodontol* 2000. 2014 Oct;66(1):203-13. doi: 10.1111/prd.12051.
11. Shahidi, Zamiri, Abolvardi, Akhlaghian, Paknahad. Comparison of Dental Panoramic Radiography and CBCT for Measuring Vertical Bone Height in Different Horizontal Locations of Posterior Mandibular Alveolar Process. *J Dent (Shiraz)*. 2018 Jun;19(2):83-91.
12. Jacobs R, Salmon B, Codari M, Hassan B, Bornstein MM. Cone beam computed tomography in implant dentistry: recommendations for clinical use. *BMC Oral Health*. 2018;18:88.

13. Horner K, Islam M, Flygare L, Tsiklakis K, Whaites E. Basic principles for use of dental cone beam computed tomography: consensus guidelines of the European Academy of Dental and Maxillofacial Radiology. *Dentomaxillofacial Radiology* (2009) 38, 187-195
14. Sammartino G, Wang HL, Citarella R, Lepore M, Marenzi G. Analysis of occlusal stresses transmitted to the inferior alveolar nerve by multiple threaded implants. *J Periodontol*. 2013 Nov;84(11):1655-61. doi: 10.1902/jop.2013.120611.



Dr. Mark Nicolucci is Oral Health's board member for implantology. He is a graduate of the University of Western Ontario and received his specialty certificate from Temple University in periodontology and oral implantology. He has a masters in oral biology and lectures regularly in the Toronto area. He maintains a full-time specialty practice in West Toronto.