

Peri-Implantitis: Treatment Options

Mark Nicolucci, BSc, DDS, MS, FRCD(C)

Peri-implantitis has been defined as a localized lesion involving bone loss around an osseointegrated implant.¹ Its prevalence has been widely reported⁴ depending on the chosen threshold and specific study, varying from as low as two percent² to as high as 58 percent³ of implants. Although a well-accepted threshold and prevalence is currently unavailable, it would appear that peri-implantitis occurs in about one out of every 10 implants.²⁻⁴ Despite this high frequency, treatment options for peri-implantitis are poorly stud-

ied. A 2011 Cochrane review concluded that the evidence available on peri-implantitis treatment is of insufficient quality and quantity and that more research is needed.²⁸

Peri-implantitis is not only frequent, but a serious complication. Implants have the potential to last a patient's entire life and peri-implantitis can lead to disintegration and early loss of implants and their supported prostheses. To treat such lesions, one may approach it similarly to periodontitis as both diseases share

many features. Both diseases can be initiated with periodontal pathogens and both have similar clinical presentations, including deep probing depths and bleeding. Even the microbiology cultivated from both are similar.^{5,27} But histologically and pathologically the diseases vary. The microbiology of peri-implantitis is more diverse than that of periodontitis, with lower levels of red complex species.²⁶ Histologically, peri-implantitis is much more infiltrative near the alveolar crest and often lacks a protective layer of tissue over the bone as we typically

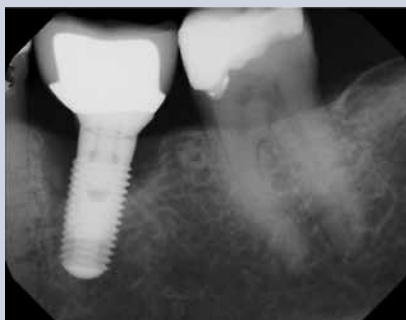

FIGURE 1A—Peri-implantitis affecting an implant at position 36.

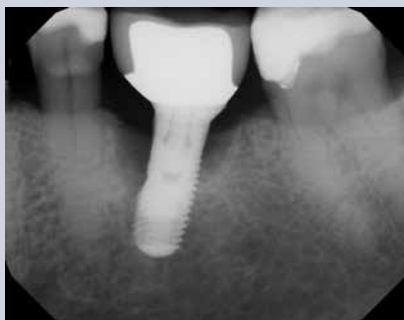

FIGURE 1B—Radiograph after implantoplasty procedure. The threads on the distal of the implant are engaged in sound lingual bone and not removed.

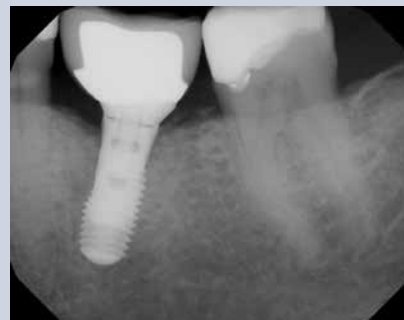

FIGURE 1C—Six month post-operative radiograph demonstrating nearly complete regeneration of the defect.

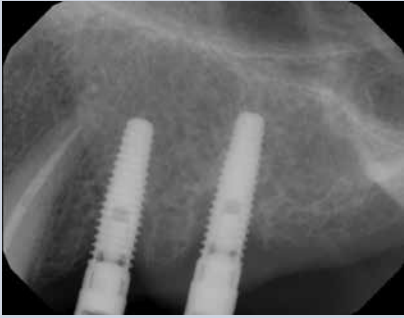

FIGURE 2A—Peri-implantitis affecting two implants at positions 24 and 25 extending 25 to 50 percent of the length of both implants. The bone is thin oral-facially and the defects have only 2-walls.

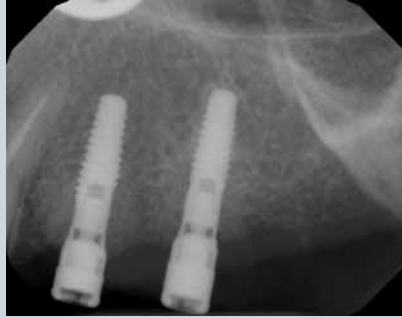

FIGURE 2B—Post-operative radiograph after implantoplasty and guided bone regeneration.

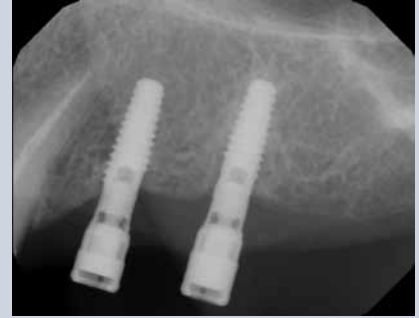

FIGURE 2C—Six month post-operative radiograph demonstrating a combination of crestal bone loss and regeneration of the apical component of the defect. Crestal bone loss is more common when lacking good regeneration conditions.

see in periodontitis.^{5,6} But most importantly to clinicians, the diseases do not respond to treatment similarly.

Peri-implantitis lesions do not respond well to improved oral hygiene and professional cleanings as is highly effective with periodontitis.^{7,19} This is not to understate the importance of oral hygiene and professional maintenance in the prevention of peri-implantitis. But once peri-implantitis develops, conservative therapy appears ineffective. Non-surgical treatment of peri-implantitis using laser or air abrasive systems has shown poor results.⁸ Studies evaluating chemotherapeutics and mechanical debridement show minimal resolution.⁷ A recent study attempting the use of photodynamic therapy to treat peri-implantitis lesions was also unsuccessful.⁹ In summary, non-surgical treatments have not been able to predictably arrest peri-implantitis.⁷

The only treatment that appears effective at resolving peri-implantitis appears to be surgical therapy. But surgical resective therapy is only partially effective. In 2003, Leonhardt found surgical and antimicrobial

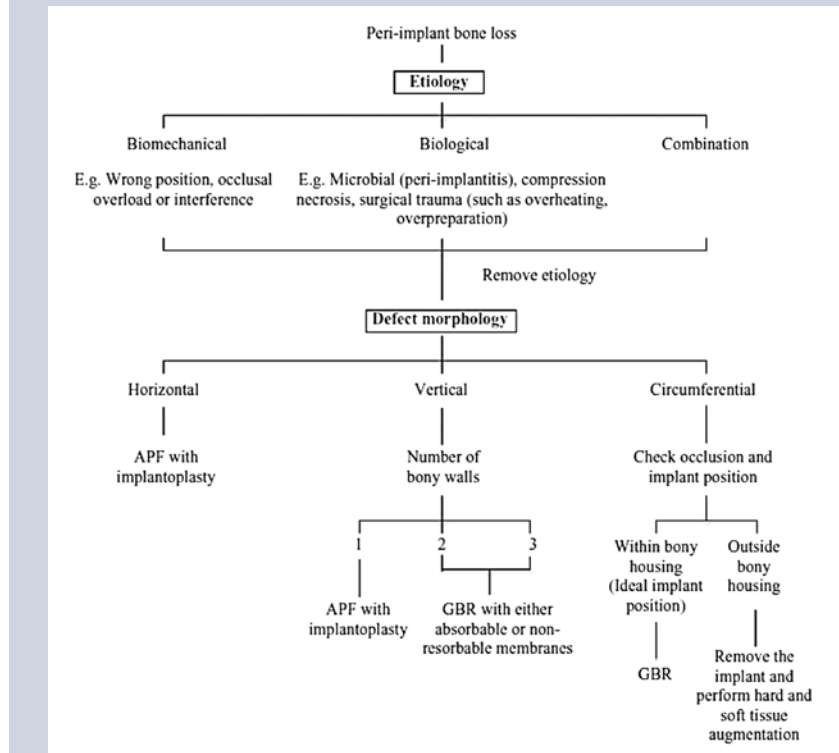


FIGURE 3. Decision tree on peri-implantitis management from Aljateeli et al., in the paper “Managing Peri-Implant Bone Loss: Current Understanding.”¹⁵

treatment effective in just over half of peri-implantitis lesions over a period of five years. Heitz-Mayfield et al. (2008) showed that an antimicrobial protocol with surgical flap access was able to stop the progression of peri-implantitis in 90 percent of cases for the short term (one year), but bleeding on probing

persisted in nearly 50 percent of those cases.¹⁰ Similar results were found by other authors.¹¹ Although a resective surgical approach appears to improve results, it is the combination of surgical access and regenerative procedures that we have seen the most success with. Schwarz et al. (2008) found regenerative surgi-

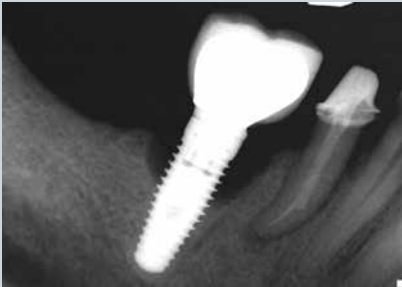

FIGURE 4A—Peri-implantitis affecting the implant at position 46.

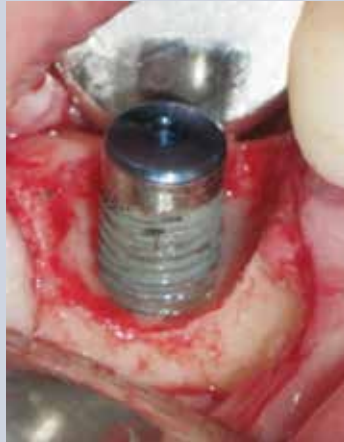

FIGURE 4B—Exposure of the 46 implant defect after debridement.

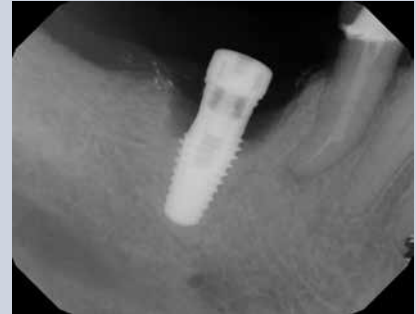

FIGURE 4C—Radiograph of the 46 implant after implantoplasty.

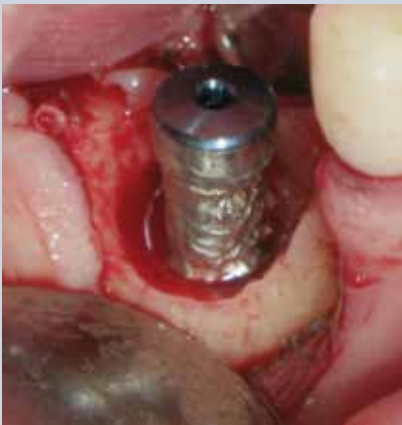

FIGURE 4D—Clinical image of the 46 implant after implantoplasty.

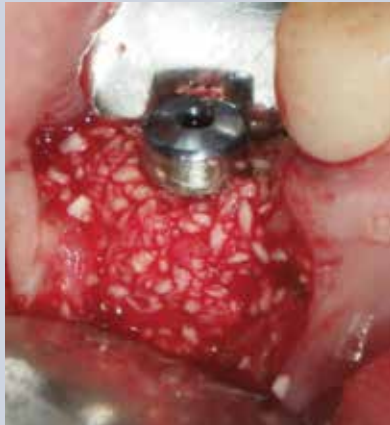

FIGURE 4E—An allograft bone particulate placed into the defect site.

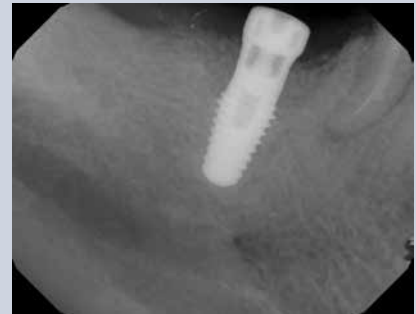

FIGURE 4F—Radiograph of the 46 implant after implantoplasty with bone graft in place.

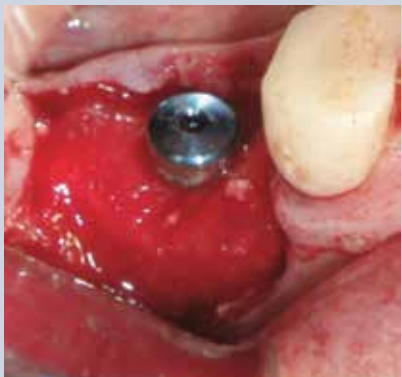

FIGURE 4G—A resorbable membrane is placed around the implant and over the bone graft.

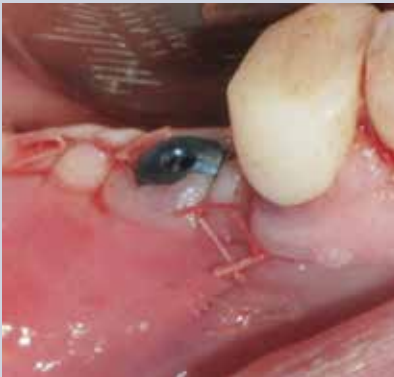

FIGURE 4H—Post-operative image after flap closure and suturing.

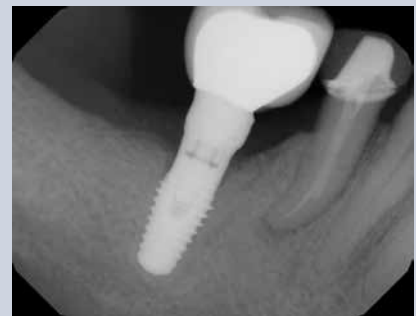

FIGURE 4I—Six month post-operative radiograph with reattachment of the original crown. Partial bone regeneration of the lesion is demonstrated.

cal treatment to be effective over two years, resulting in cessation of peri-implant bone loss and a reduction of bleeding on probing from 80 percent to 34 percent.¹² Froum et al. (2012) also

demonstrated the effectiveness of surgical regeneration where he arrested peri-implantitis and reduced bleeding on probing over three to seven years¹³ (Figs. 1A–2C).

Unfortunately, not all peri-implantitis lesions are favourable to regeneration. For implants with thin facial and lingual walls, peri-implantitis typically does not produce a crater-form

defect with four walls. In some of these cases, the defect will present as a complete loss of the surrounding bony walls leaving regeneration as an unpredictable treatment choice. Aljateeli et al. (2012) proposed a decision tree based upon the defect morphology.¹⁵ If the defect had sufficient walls (two or greater), regeneration was attempted, but if there was zero or one wall, an apically positioned flap (APF) was suggested with implantoplasty (i.e., drilling the implant surface to remove the threads and outer surface).¹⁵ The theoretical benefit of implantoplasty is the production of a surface that is less adherent to bacterial colonization and a form of surface decontamination.

Charalampakis et al. (2011) evaluated the longevity and incidence of relapse of multiple different treatments on peri-implantitis lesions.²⁷ Over half of the cases he evaluated relapsed and were not controlled. Smoking and early disease development were associated with higher rates of relapse and surgical therapy with lower rates of relapse.²⁷ This means peri-implantitis is not just hard to treat, but treated cases must be watched closely as relapse is common (Fig. 3).

In all of the treatments proposed, one of the critical steps was always surface decontamination. The complex modern surface topography of implants offers an excellent haven for bacterial growth and the decontamination of such surfaces can be difficult, especially non-surgically. We have several options for surface decontamination. Anti-infective treatments aim to detoxify the implant surface, such as with chlorhexidine, tetracycline, metronidazole, citric acid, laser and photodynamic

therapy. Mechanical debridement aims to remove the biofilm wholly, such as with titanium, plastic or steel curettes, saline rinse, cotton gauze, air abrasion, or implantoplasty. Many clinicians will choose a combination of treatments in an attempt to ensure that surface decontamination is successful.

Multiple studies have evaluated the efficacy of the different surface treatments. Schwarz et al. (2011) compared surface decontamination using laser (Er:YAG) versus plastic curettes with saline-soaked cotton pellets and found no difference in outcome.¹⁶ Meyle (2012) performed a literature review comparing different surface treatments and found no difference between mechanical debridement, antiseptic

port these findings.

Recently (2013), Schwarz et al. used a combination of implantoplasty of the coronal non-regenerable portion of peri-implant defects and grafting the regenerable apical portion to show excellent short-term results.²⁴ But the implantoplasty was only used for the anticipated supracrestal portion of the implant, as suggested by Aljateeli et al.'s decision tree¹⁵ to reduce bacterial adhesion. There was no evaluation of the impact of implantoplasty as an effective means of surface decontamination (Figs. 4A–4I).

Implantoplasty provides an absolute decontamination of the implant surface, but four concerns exist: heat production, deposit of implant material into the surgi-

Many clinicians will choose a combination of treatments in an attempt to ensure that surface decontamination is successful

use, air abrasion, photodynamic or laser therapy.¹⁹ However, one study did find positive results comparing implantoplasty as a surface decontamination versus mechanical debridement. Romeo et al. (2005, 2007) demonstrated that implantoplasty improved surgical non-regenerative treatment of peri-implantitis, reducing probing depths from 5.5 to 3.6mm and the average bleeding index from 2.3 to 0.5.^{17,18} In Claffey et al.'s 2008 review of surgical treatments of peri-implantitis, he states, "...[implantoplasty] could be of value when treating peri-implantitis and should be considered."²¹ Unfortunately, no further comparative research has been conducted on implantoplasty to sup-

cal field, damage to the implant surface and weakening of the implant structure. Heat production is easily managed by effective irrigation and appropriate bur selection.²⁰ In a dog study,²² titanium debris from implantoplasty produced a histological inflammatory cell infiltrate in adjacent tissue but the debris was very minor, undetectable via computed tomography. Both Schwarz¹⁶ and Romeo¹⁸ have suggested these depositions are not associated with any adverse events clinically. Implantoplasty removes the micro- and macro-roughened implant surface but this is commonly thought of as desirable, reducing the roughness of the surface to discourage bacterial colonization.²⁵ The final

concern of weakening the implant structure is not often discussed because the amount of surface that needs to be removed is very minimal.

Despite these explanations, few articles discuss implantoplasty. As of the writing of this article, a PubMed literature search on the term “implantoplasty” only provides 11 articles, although that is likely to increase in the future. Implantoplasty can be considered a useful adjunct in resective surgery to smooth and decontaminate portions of an implant left exposed by peri-implantitis lesions. It also may be a beneficial form of decontamination for the whole peri-implant lesion, improving surgical results. Further research is needed to validate the evidence shown by Romeo et al.

Implantoplasty removes the micro and macro-roughened implant surface but this is commonly thought of as desirable, reducing the roughness of the surface to discourage bacterial colonization

Implants have become the superior treatment choice in many cases of edentulism. With the increasing number of implants being placed, peri-implantitis has become much more prevalent. The multitude of treatment options, lack of strong scientific evidence and high incidence of relapse make peri-implantitis a priority to understand. Our ability to successfully and predictably treat this disease will provide a significant benefit to a large portion of our implant patients. **OH**

Dr. Mark Nicolucci graduated from the University of Western Ontario dental school in 2006 and continued his education with a residency at Temple University in

Philadelphia. In 2010, he graduated from Temple University's periodontology program with a certificate in Periodontology and Oral Implantology. He received a Masters in oral biography and became a diplomat of the International Congress of Oral Implantology and a Fellow of the Misch International Implant Institute. Since returning to Canada, Dr. Nicolucci has been active in lecturing and attending seminars both locally and internationally. He currently works in west Toronto.

Oral Health welcomes this original article.

REFERENCES

1. Misch CE, Perel ML, Wang HL, et al. Implant success, survival, and failure: the International Congress of Oral Implantologists (ICOI) Pisa Consensus Conference. *Implant Dent* 2008; 17:5–15.
2. Astrand P, Ahlqvist J, Gunne J, Nilson H. Implant treatment of patients with edentulous jaws: A 20-year follow-up. *Clin Implant Dent Relat Res* 2008;10:207-217.
3. Koldslund OC, Scheie AA, Aass AM. Prevalence of Peri-Implantitis Related to Severity of the Disease With Different Degrees of Bone Loss *J Periodontol* 2010;81:231-238.
4. Zitzmann NU, Berglundh T. Definition and prevalence of peri-implant diseases. *J Clin Periodontol* 2008; 35 (Suppl. 8): 286–291.
5. Berglundh T, Zitzmann NU, Donati M. Are peri-implantitis lesions different from periodontitis lesions? *J Clin Periodontol* 2011; 38 (Suppl. 11): 188–202.
6. Lang NP, Berglundh T on Behalf of Working Group 4 of the Seventh European Workshop on Periodontology: Periimplant diseases: where are we now? – Consensus of the Seventh European Workshop on Periodontology. *J Clin Periodontol* 2011; 38 (Suppl. 11): 178–181.
7. Renvert S, Roos-Jansaker AM, Claffey N. Non-surgical treatment of peri-implant mucositis and peri-implantitis: a literature review. *J Clin Periodontol* 2008; 35 (Suppl.8): 305–315.
8. Renvert S, Lindahl C, Roos Jansaker AM, Persson GR. Treatment of peri-implantitis using Er:YAG laser or an air-abrasive device: a randomized clinical trial. *J Clin Periodontol* 2011; 38: 65–73.
9. Deppe H, Mucke T, Wagenpfeil S, Kesting M, Sculean A. Nonsurgical antimicrobial photodynamic therapy in moderate vs severe peri-implant defects: A

- clinical pilot study. *Quintessence Int.* 2013 Mar 27. [Epub ahead of print]
10. Heitz-Mayfield LJA, Salvi GE, Mombelli A, Faddy M, Lang NP. Anti-infective surgical therapy of peri-implantitis. A 12-month prospective clinical study. *Clin. Oral Impl. Res.* 23, 2012; 205–210.
11. Maximo, MB, de Mendonca, AC, Santos VR, Figueiredo LC, Feres M, Duarte M. Short-term clinical and microbiological evaluations of peri-implant diseases before and after mechanical anti-infective therapies. *Clinical Oral Implants Research* 2009; 20: 99–108.
12. Schwarz F, Sculean A, Bieling K, Ferrari D, Rothamel D, Becker J. Two-year clinical results following treatment of peri-implantitis lesions using a nanocrystalline hydroxyapatite or a natural bone mineral in combination with a collagen membrane. *J Clin Periodontol* 2008; 35: 80–87.
13. Froum SJ, Froum SH, Rosen P. Successful management of peri-implantitis with a regenerative approach: a consecutive case series of 51 treated implants with 3- to 7.5-year follow-up. *Int J Periodontics Restorative Dent* 2012;32:11-20
14. Leonhardt A. Five-year clinical, microbiological, and radiological outcome following treatment of peri-implantitis in man. *J Periodontol* 2003; 74:1415-1422.
15. Aljateeli M, Fu JH, Wang HL. Managing Peri-Implant Bone Loss: Current Understanding. *Clin Implant Dent Relat Res.* 2012 May;14 Suppl 1:e109-18.
16. Schwarz F, Sahn N, Ighaut G, Becker J. Impact of the method of surface debridement and decontamination on the clinical outcome following combined surgical therapy of peri-implantitis: a randomized controlled clinical study. *J Clin Periodontol* 2011; 38:276–284.
17. Romeo E, Ghisolfi M, Murgolo N, Chiapasco M, Lops D, Vogel G. Therapy of peri-implantitis with resective surgery. A 3-year clinical trial on rough screw-shaped oral implants. Part I: clinical outcome. *Clin Oral Implants Res* 2005; 16:9–18.
18. Romeo E, Lops D, Chiapasco M, Ghisolfi M, Vogel G. Therapy of peri-implantitis with resective surgery. A 3-year clinical trial on rough screw-shaped oral implants. Part II: radiographic outcome. *Clin Oral Implants Res* 2007; 18:179–187.
19. Meyle, J. Mechanical, chemical and laser treatments of the implant surface in the presence of marginal bone loss around implants. *Eur J Oral Implantol.* 2012;5 Suppl:S71-81.
20. Sharon E, Shapira L,Wilensky A, Abu-Hatoum R, Smidt A. Efficiency and thermal changes during implantoplasty in relation to bur type. *Clin Implant Dent Relat Res* 2011.
21. Claffey N, Clarke E, Polyzois I, Renvert S. Surgical treatment of peri-implantitis. *Journal of Clin Perio* 35, 316–332.
22. Schwarz F, Sahn N, Mihatovic I, Golubovic V, Becker J. Surgical therapy of advanced ligature-induced peri-implantitis defects: cone-beam computed tomographic and histologic analysis. *J Clin Periodontol* 2011; 38: 939–949.
23. Suh JJ, Simon Z, Jeon YS, Choi BG, Kim CK. The use of implantoplasty and guided bone regeneration in the treatment of peri-implantitis: two case reports. *Implant Dent* 2003;12(4):277-82.
24. Schwarz F, Sahn N, Becker J. Combined surgical therapy of advanced peri-implantitis lesions with concomitant soft tissue volume augmentation. A case series. *Clin Oral Implants Res.* 2013 Jan 27. [Epub ahead of print]
25. Meier RM, Pfammatter C, Zitzmann NU, Filippi A, Kuhl S. Surface quality after implantoplasty. *Schweiz Monatsschr Zahnmed (Research and Science)* 2012;122:714-719
26. Koyanagi T, Sakamoto M, Takeuchi Y, Maruyama N, Ohkuma M, Izumi Y. Comprehensive microbiological findings in peri-implantitis and periodontitis. *J Clin Periodontol* 2013; 40 (3):218-226
27. Charalampakis G, Rabe P, Leonhardt A, Dahle'n G. A follow-up study of perimplantitis cases after treatment. *J Clin Periodontol* 2011; 38: 864–871.
28. Esposito M, Grusovin MG, Worthington HV. Treatment of peri-implantitis: what interventions are effective? *A Cochrane systematic review.* *Eur J Oral Implantol* 2012;5 Suppl:S21-41.